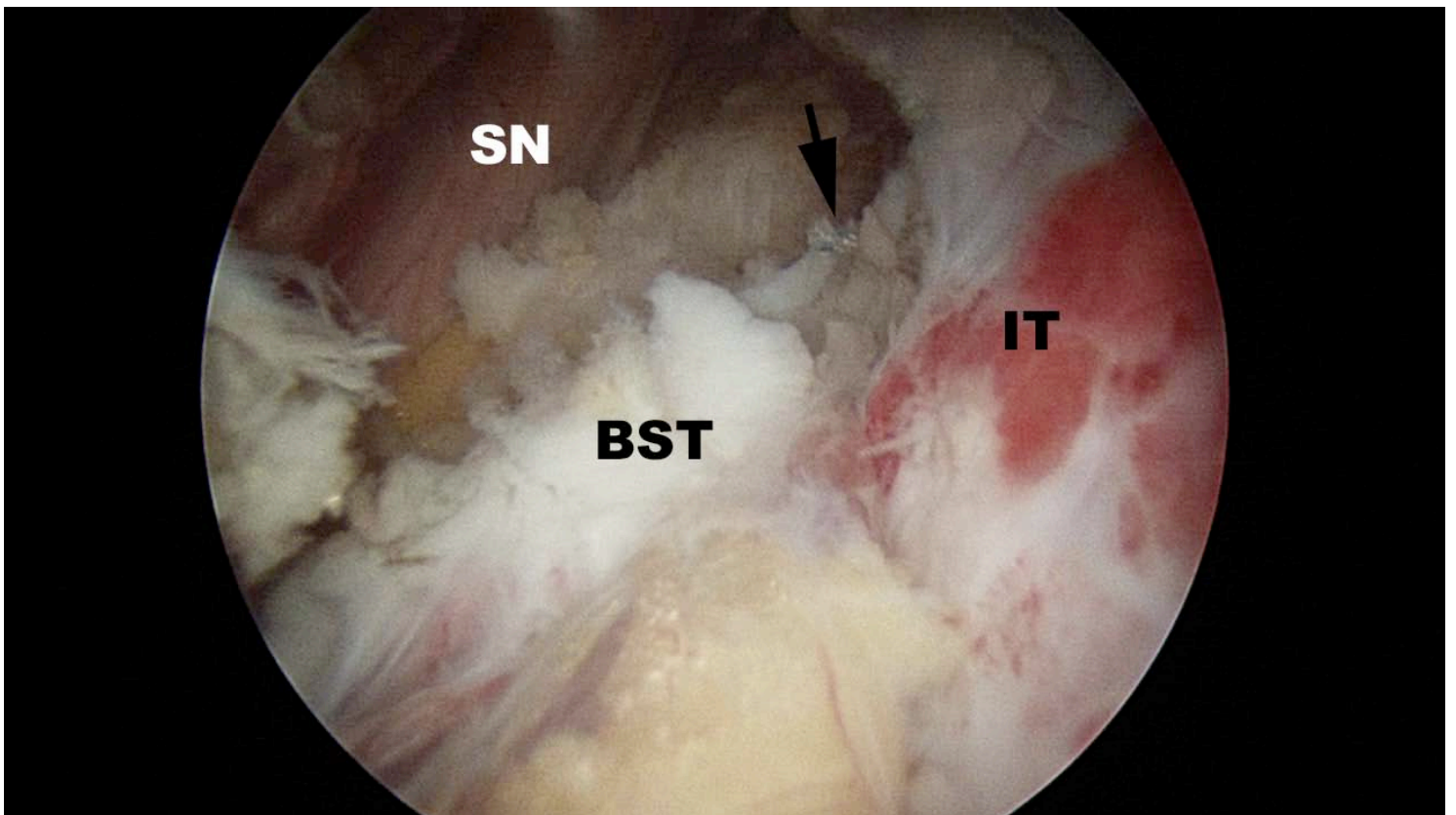
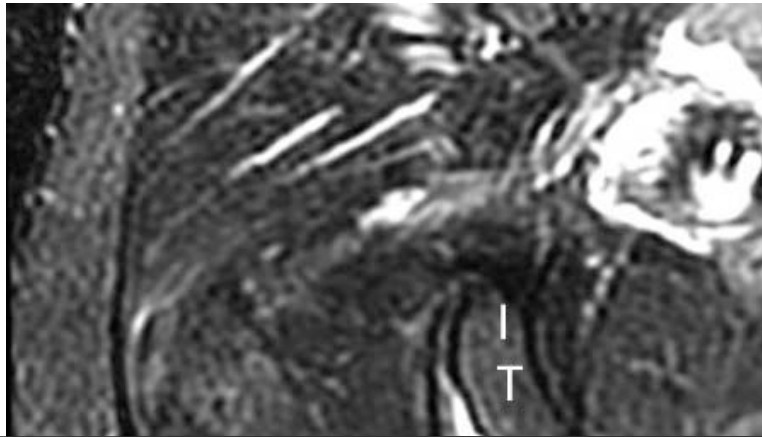


Endoscopic Hamstring Repair

Carlos A. Guanche, MD
Southern California Orthopedic Institute





Endoscopic Hamstring Repair

With the expansion of knowledge regarding hip pathologies as a result of the increased treatment of hip problems arthroscopically has come an expanded treatment of many injuries that were previously treated through open methods. The treatment of symptomatic ischial bursitis and hamstring injuries is one such area. In this paper, the author describes the surgical procedure and discusses the findings and preliminary outcomes in a group of the first 15 patients undergoing the procedure. The clinical rationale associated with the treatment algorithm is also discussed.

Hamstring injuries have been effectively addressed in the past with a variety of open methods.(1,2) However, the endoscopic management of much pathology previously treated with more invasive, open approaches has evolved. The technique described in this chapter is another such evolution.

Hamstring injuries are common and can affect all levels of athletes. (3-7) There is a continuum of hamstring injuries that can range from musculotendinous strains to avulsion injuries. (3,4) Most hamstring strains do not require surgical intervention and resolve with a variety of modalities and rest. (3-7) In some patients, chronic pain can occur at the hamstring origin from either partial or complete tears as well as from chronic ischial bursitis. The technique described in this chapter allows for the treatment of many of these problems in an endoscopic fashion, with a minimum of risk and maximum diagnostic capability.

The hamstrings originate from the ischial tuberosity and insert distally below the knee on the proximal tibia, with the exception of the short head of the biceps femoris. The tibial branch of the sciatic nerve innervates the semitendinosus, semimembranosus, and the peroneal branch of the sciatic nerve innervates the long head of the biceps femoris.(5)

The proximal hamstring complex has a strong bony attachment on the ischial tuberosity (Figure 1).

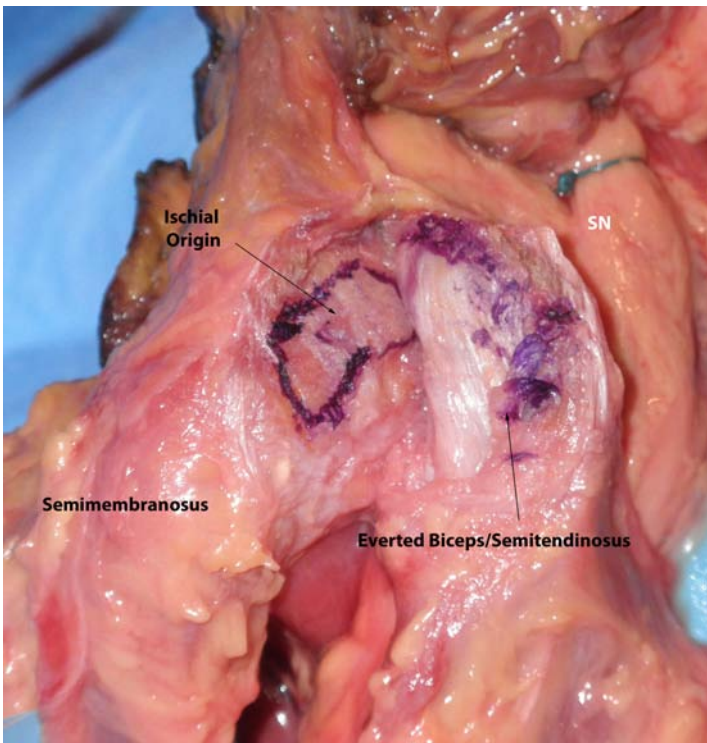


Figure 1A: The anatomy of the hamstring origin showing the common biceps and semitendinosus as well as the separate semimembranosus origin.

The footprint on the ischium includes the semitendinosus and the long head of biceps femoris, which begin as a common proximal tendon and footprint, and a distinct semimembranosus footprint.(8) The semimembranosus footprint is medial (and posterior) to the crescent-shaped footprint of the common origin of the semitendinosus and long head of the biceps femoris, which is more lateral. (Figure 1)

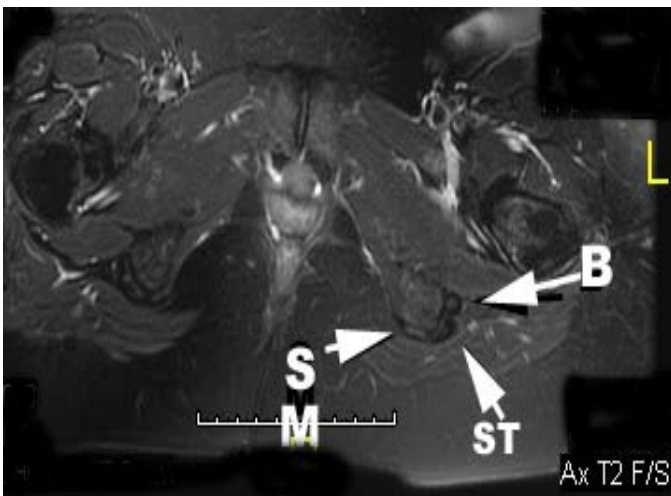


Figure 1B

Axial T2 weighted magnetic resonance image depicting the anatomy of the hamstring origin in a left hip. SM: origin of Semimembranosus; B: Biceps origin; ST: Semitendinosus

Most acute injuries usually involve a traumatic event that includes forced hip flexion and knee extension. Most commonly, this has been described in waterskiing.(9, 10) However, the injury can result from any sporting activity that require rapid acceleration and deceleration.(10, 11)

Proximal hamstring tears can be categorized as complete avulsions, partial avulsions, apophyseal avulsions, and degenerative (tendinosis) avulsions.(11) Degenerative tears of the hamstring origin are insidious in onset and are commonly seen as an overuse injury, especially in runners. The mechanism of injury, presumably, is repetitive irritation of the medial aspect of the hamstring tendon (along the lateral aspect of the tuberosity, where the bursa resides). This causes an attritional tear of the tendon and subsequent chronic pain.

Commonly, athletes with proximal hamstring tendon tears describe a popping or tearing sensation with associated acute pain and bruising over the posterior hip.(13, 14)

Occasionally, patients who present with either acute or chronic tears may complain of a pins and needles sensation in the sciatic nerve distribution, much like sciatica.(14, 15) This may be due to acute compression from hematoma in the proximity of the sciatic nerve or chronic scarring and tethering of the tendon to the nerve. Similarly, symptoms of ischial bursitis include buttock or hip pain, as well as localized tenderness overlying the ischial tuberosity. Additional symptoms of chronic ischial bursitis may include tingling into the buttock that spreads down the leg.(14)

Advanced imaging is crucial in cases of partial tears with chronic pain. Standard radiographs of the pelvis and a lateral of the affected hip are performed first to rule out any bony problems, especially avulsions of the ischial tuberosity in younger patients. (Figure 2) Most commonly, no fractures are identified and MRI is utilized to assess the proximal hamstring origin. A complete rupture of all three tendons is common and easily identified on MRI.

Partial hamstring origin tears, however, are more difficult to discern. In two tendon tears, which commonly have an associated musculotendinous junction injury to the third tendon (semimembranosus), this is especially difficult. Most commonly, there is an avulsion of the common semitendinosus and biceps origin, with the semimembranosus remaining intact.(7) Partial tears without any significant retraction can be seen on MRI as a sickle sign, and are partial avulsions of the semimembranosus. (Figure 3)

Nonoperative treatment is most commonly recommended in the setting of low-grade partial tears and insertional tendinosis. Initial treatment consists of relative rest, oral non-steroidal anti-inflammatory medications and a physical therapy regime.(16) An ultrasound-guided corticosteroid

injection may be used and has been shown to provide initial relief in up to 50% of patients at one month.(17) Partial tears that remain symptomatic may benefit from surgical debridement and repair, similar to other commonly seen partial tendon tears (patella, quadriceps, and biceps).(18)

There are several series and descriptions of open surgical techniques that are available.(12, 13, 14, 19, 20-22) To date, there has been no report of endoscopic management of these injuries. After developing experience in the open management of these injuries, the author has developed an endoscopic technique that allows a safe approach to the problematic area. The benefits of this endoscopic approach, without elevating the gluteus maximus and with the use of endoscopic magnification to protect the sciatic nerve, may improve the management of these injuries and reduce morbidity.

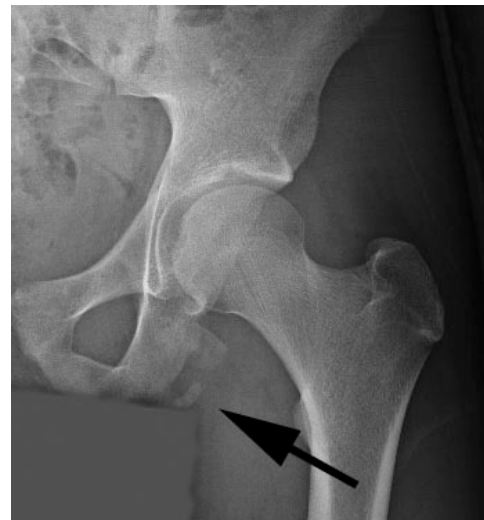

Figure 2: Bony Avulsion of the ischium in a young runner

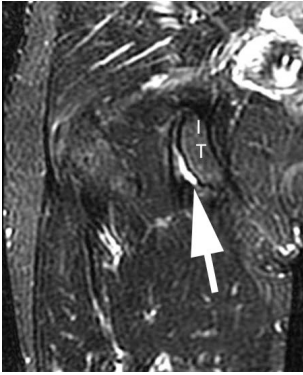
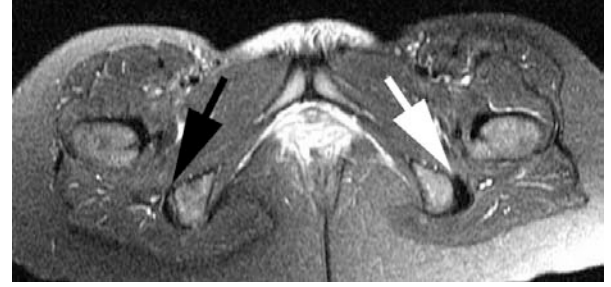

Figure 3: MRI views of a partial insertional tear with a sickle sign, indicating fluid within the ischial bursa.

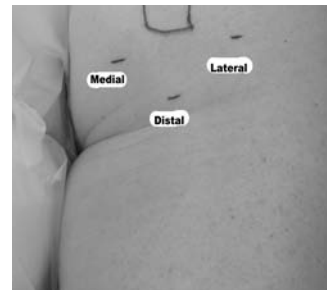
Left: A coronal T2 weighted view of a right hip showing the sickle sign (white arrow). IT: Ischial tuberosity.

Right: Axial T2 weighted view showing both ischial tuberosities. Note the side with the black arrow showing the sickle sign and the normal side for comparison (white arrow).

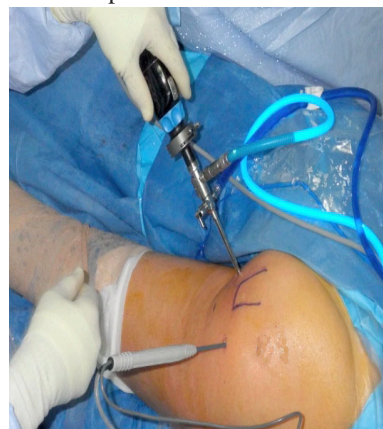

The patient is positioned prone on a standard table that is flat. Bolsters are placed under the chest to support the torso. No effort is made to flex the hips, as this may decrease the potential distance between the ischium and the gluteus maximus, thus obliterating this potential working space. The posterior aspect of the hip is then draped assuring that the leg and thigh are free and can be freely manipulated during the procedure. (Figure 4)

SURGICAL TECHNIQUE



Two portals are created, two cm medial and lateral to the palpable ischial tuberosity. (Figure 5) A blunt arthroscopic cannula is inserted into the lateral portal and a blunt switching stick in the medial portal. The instruments aim to localize the most prominent aspect of the ischium where the sciatic nerve is furthest away. The lateral portal is first used for the arthroscope and the sub muscular plane between the gluteus maximus and ischium is developed. The prominence of the tuberosity is identified and lateral borders are delineated.



between the gluteus ischium is developed. prominence of the tuberosity is identified and lateral borders are

Endoscopic Repair leads to improved visualization of the sciatic nerve and a complete assessment of any underlying sciatic nerve entrapment.

A 30° arthroscope is employed from the lateral portal and an electrocautery device is placed in the medial portal. Any remaining fibrous attachments between the ischium and the gluteus muscle are released, staying along the central and medial portions of the ischium to avoid coming near sciatic nerve, which is well lateral (and anterior) to the ischial prominence. Once the tip and medial aspect of the ischium are delineated, the lateral aspect is then exposed with the use of a switching stick as a soft tissue dissector. With the lateral aspect identified, the dissection continues anteriorly and laterally towards the sciatic nerve. (Figure 6) A careful release of any soft tissue bands is performed in a proximal to distal direction in order to mobilize the nerve and protect it

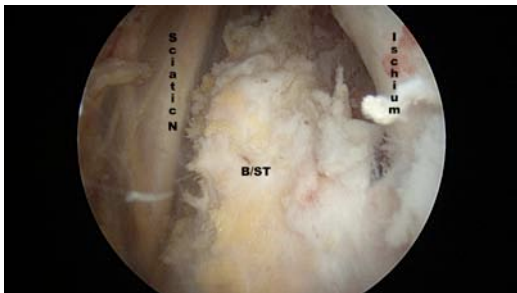
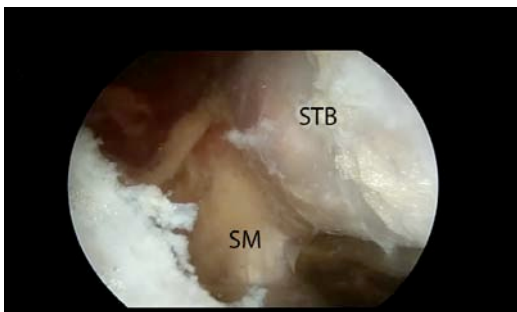
Figure 6: Endoscopic views of the subgluteal space in a left hip. The arthroscope is in the lateral portal.

- A. The sciatic nerve (SN) has been exposed along with biceps and semitendinosus avulsion (BST) and the lateral ischium (I).
 B. The separate attachments of the semimembranosus (SM) tendon, which is more anterior and medial, and the common biceps and semitendinosus (BST) tendon more posterior and lateral.



throughout the exposure and ultimate repair of the hamstring tendon(s). This is especially important in cases of acute avulsions, where the nerve may be caught in the healing response to the tear. The posterior femoral cutaneous nerve is often the first branch of the nerve identified during dissection, and serves as a harbinger of the main sciatic nerve.

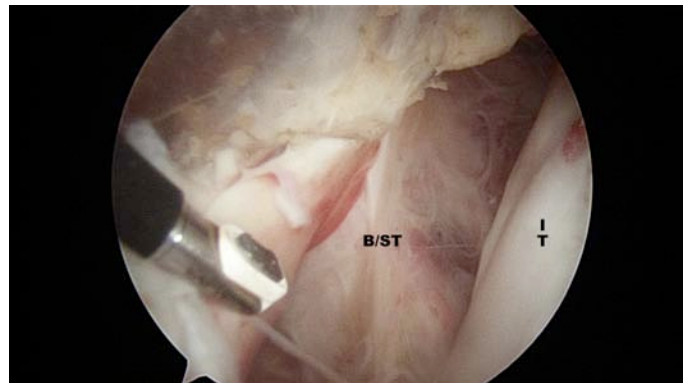


Figure 7: Endoscopic view of a proximal hamstring origin avulsion in a left hip with the arthroscope in the lateral portal. The distal end of the ischium is seen with fibrous tissue attachment (IT) and the avulsed ischial origin of the common tendon is seen to the left (B/ST).

With the nerve identified and protected, the tendinous origin is then inspected for any obvious tearing. (Figure 7) In acute tears, the tear is obvious and the tendon is often retracted distally. In these cases, there may be a large hematoma that requires evacuation..

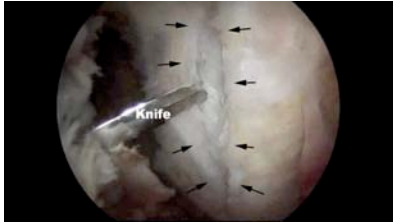
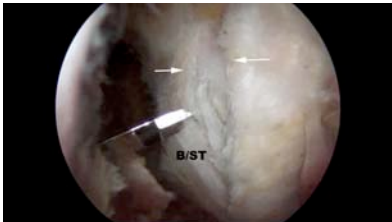


Figure 8: Endoscopic views of the proximal hamstring origin in a left hip

Above, the knife has been inserted through the distal portal and the tendon (biceps/semitendinosus) attachment has been incised (along the arrows).

Below, the common biceps/semitendinosus origin has been elevated (seen between the arrows). B/ST: Biceps/Semitendinosus complex



Once the area of pathology is identified (in incomplete tears), an endoscopic knife can be employed to longitudinally split the tendon along its fibers.(Figure 8) This area can be identified through palpation, as there is typically softening over the detachment, making the tissue ballotable against the ischium. The hamstring footprint is then undermined and the partial tearing and lateral ischial wall are debrided with an oscillating shaver and burr, if necessary. The devitalized tissue is removed and a bleeding cancellous bed is created in preparation for tendon repair. The more distal and inferior ischium and bursa can also be resected and cleared of inflamed tissue. By retracting the tissues, the bursa can be entered and resected. (Figure 9)

A more inferior portal can then be created approximately four cm distal to the tip of the ischium and equidistant from the medial and lateral portals.(Figure 5) This portal is employed either for insertion of suture anchors or suture management. Suture passing devices and instruments typically used in arthroscopic rotator cuff repair are then employed to prepare for the tissue approximation. Once all of the sutures are passed through the tissue of the avulsed hamstring, the sutures are tied and a solid repair of the tendon can be effected. In general, one suture anchor is used per centimeter of detachment. (Figure 10)

Postoperatively, the patient is fitted with a hinged knee brace fixed at 90° of flexion for four weeks and the patient is non-weight-bearing. In larger repairs, consideration may be given to using a hip, knee, ankle, foot orthosis (HKAFO). At four weeks, the knee is gradually extended by about 30° per week in order to allow full weight bearing by six to eight weeks, while maintaining the use of crutches. Physical therapy is instituted at this point, with the initial phase focused on hip and knee range of motion. Hamstring strengthening is begun at ten to twelve weeks, predicated on full range of motion and a painless gait pattern. Full, unrestricted activity is allowed at approximately four months.

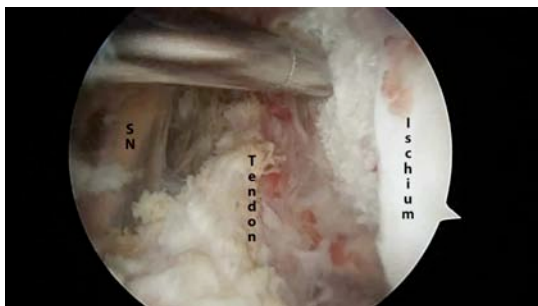
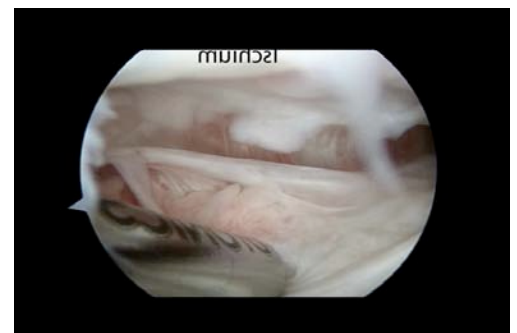

Figure 9:

To the left, the common BST (Tendon) origin has been incised and elevated. Note the tool is serving to retract the detached tissue. SN: Sciatic Nerve

To the right, Ischial bursa prior to debridement. Note the hypertrophic inflammatory tissue in the bursal space.



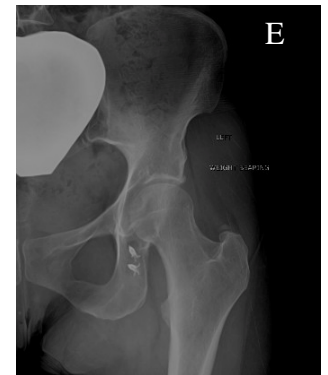
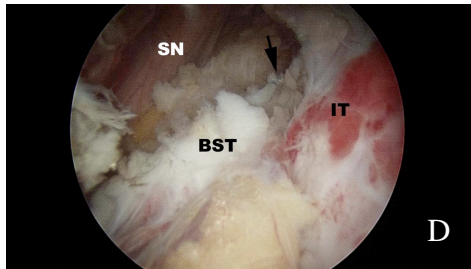
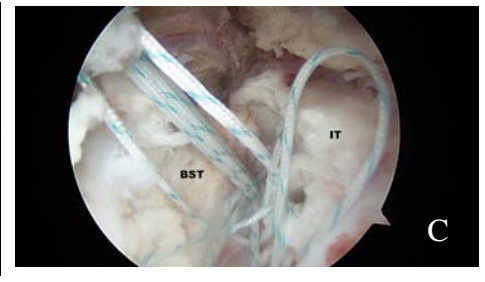
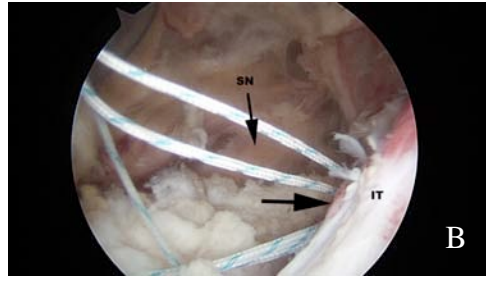
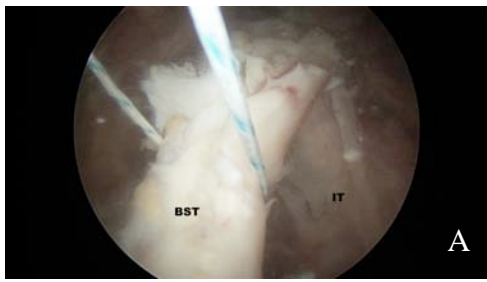


Figure 10: Endoscopic view of repair of the proximal hamstring origin in a left hip with the arthroscope in the lateral portal.

- A. The ischium has been prepared and the first suture is in place, retracting the avulsed tendon (BST). IT: Ischial Tuberosity
- B. Multiple sutures in place and passed through the tendon. Note the proximity of the sciatic nerve (SN) to the repair site. The arrow at the ischial tuberosity (IT) indicates the first anchor insertion point.
- C. Final mattress sutures in place in the substance of the tendon. Multiple sutures are in place and are to be tightened with knotless anchor configuration. (IT: Ischial tuberosity; BST: Biceps/Semitendinosus)
- D. Final tendon repair with the tendon edges reattached to the ischial footprint with a suture visualized (arrow). The sciatic nerve (SN) is seen to the left. (IT: Ischial tuberosity; BST: Biceps/Semitendinosus)
- E. Radiograph of suture anchors in place on the ischial tuberosity.

PATIENTS AND METHODS

Over the last eighteen months, the procedure has been employed in a group of fifteen patients. The first indication is an acute hamstring avulsion in an active patient with greater than two centimeters of retraction (three patients). In nine patients, there was a clinically evident partial hamstring avulsion involving the biceps/semitendinosus tendon, with refractory ischial pain and inability to return to high level sports. The final three patients had a history of refractory ischial bursitis, with no discernable tear with a failure of conservative treatment including at least six weeks of physical therapy and two guided (ultrasound) ischial injections.

RESULTS

At the index procedure, all patients underwent the surgery as described with no need to abandon the procedure as a result of failure of visualization of any of the structures. All of the patients underwent suture anchor fixation with no anchor complications to date. There were two patients that initially complained of numbness over the posterior thigh with resolution of their symptoms by six weeks postoperatively. There were no wound complications and no sciatic nerve dysfunction. One patient (with preoperative refractory ischial bursitis) has had a subsequent guided injection as a result of recurrent ischial pain.

CONCLUSIONS

The surgical approach to hamstring repairs has received limited attention. Those patients with partial tears and chronic bursitis are an even smaller percentage of hamstring problems, with few clinical studies available.(23) With the advances seen in hip arthroscopy, further development of techniques has allowed us to explore the use of the arthroscope in these previously uncharted areas.

One of the most important aspects in the treatment of proximal hamstring ruptures is early recognition and treatment. With the endoscopic technique, the management may certainly evolve to quicker repair of the problem. Patients with acute repairs have had better outcomes in the literature, when compared to chronic repair.(13, 14) Delayed complications of nonoperative treatment of proximal hamstring ruptures have been described, and these include knee flexion and hip extension weakness, difficulty sitting, and hamstring deformity.(24) The author has employed this technique successfully on several acute ruptures, as well as chronic partial tears.

Surgical repair of proximal hamstring ruptures also has its inherent risks. With open methods, superficial as well as deep wound infections can occur similar to other surgeries, however, the location of the incision can potentially increase this risk. With the endoscopic technique, this possibility is substantially lessened. Additionally, the three main nervous structures at risk of iatrogenic injury are the posterior femoral cutaneous, inferior gluteal, and sciatic nerves.(18, 25) The sciatic nerve is in close proximity to the ischial tuberosity, running along its lateral aspect. With the endoscopic technique, the need for retraction is non-existent, since the nerve is identified, visualized and protected during the repair.

A concern unique to the endoscopic approach is fluid extravasation into the pelvis as a result of the fluid used in the distension of the potential space around the hamstring tendon. The fluid inflow pump is maintained at the lowest possible setting throughout the procedure. In addition, cannulas are established with outflow suction attached at an early stage to prevent fluid egress into the soft tissues around the pathology. An effort should be made to keep track of the total fluid ingress and egress during the case. In addition the operative team should regularly check the abdomen for any evidence of distension. Likewise, any unusual blood pressure decreases may be due to fluid compression from retroperitoneal extravasation.

Through the appropriate application of this technique, many of the chronic hamstring injuries and some of the acute injuries previously addressed through a more invasive, open method can be effectively addressed endoscopically. It is also hoped that a further understanding of hamstring injuries and their sequelae can be further developed.

REFERENCES

1. Birmingham P, Muller M, Wickiewicz T, et al. Functional outcome after repair of proximal hamstring avulsions. *J Bone Joint Surg Am* 2011; 93:1819-1826.
2. Blasier RB, Morawa LG. Complete rupture of the hamstring origin from a water skiing injury. *Am J Sports Med* 1990; 18: 435-437.
3. Brown T: Thigh. *Orthopaedic Sports Medicine. Principles and Practice*, ed. Drez DD, DeLee JC, Miller MD. Vol. 2, 2003, Philadelphia: Saunders. 1481-1523.
4. Byrd JWT, Polkowski G, Jones KS: Endoscopic management of the snapping iliopsoas tendon. *Arthroscopy* 2009; e18.
5. Chakravarthy J, Ramisetty N, Pimpalnerkar A. Surgical repair of complete proximal hamstring tendon ruptures in water skiers and bull riders: a report of four cases and review of the literature. *Brit J Sports Med* 2005; 39:569-572.
6. Clanton TO, Coupe KJ. Hamstring strains in athletes: diagnosis and treatment. *J Am Acad Orthop Surg* 1998; 6: 237-248.
7. Cohen S, Bradley J. Acute proximal hamstring rupture. *J Am Acad Orthop Surg* 2007; 15:350-355.
8. Cross MJ, Vandersluis R, Wood D et al. Surgical repair of chronic complete hamstring tendon rupture in the adult patient. *Am J Sports Med* 1998; 26:785-788.
9. Elliott MC, Zarins B, Powell JW, Kenyon CD. Hamstring muscle strains in professional football players: a 10-year review. *Am J Sports Med* 2011; 39: 843-850.
10. Garrett WE, Jr. Muscle strain injuries. *Am J Sports Med* 1996; 24(6 Suppl):S2-8.
11. Garrett WE, Jr, Rich FR, Nikolaou PK, et al. Computed tomography of hamstring muscle strains. *Medicine Sci Sports Exerc* 1989; 2:506-514.
12. Harris JD, Griesser MJ, Best TM et al. Treatment of proximal hamstring ruptures - a systematic review. *Inter J Sports Medicine* 2011; 32:490-495.
13. Klingele KE, Sallay PI. Surgical repair of complete proximal hamstring tendon rupture. *Am J Sports Med* 2002; 30:742-747.
14. Konan S, Haddad F. Successful return to high level sports following early surgical repair of complete tears of the proximal hamstring tendons. *International Orthop* 2010; 34:119-123.
15. Lempainen L, Sarimo J, Heikkila J et al. Surgical treatment of partial tears of the proximal origin of the hamstring muscles. *Brit J Sports Med* 2006; 40:688-691.
16. Lempainen L, Sarimo J, Mattila K, et al. Proximal hamstring tendinopathy: results of surgical management and histopathologic findings. *Am J Sports Med* 2009; 37:727-734.
17. Martin HD, Shears SA, Johnson JC, et al. The endoscopic treatment of sciatic nerve entrapment/deep gluteal syndrome. *Arthroscopy* 2011; 27:172-181.
18. Mendiguchia J, Brughelli M. A return-to-sport algorithm for acute hamstring injuries. *Physical Therapy Sport*; 2011;12: 2-14.
19. Mica L, Schwaller A, Stoupis C, et al. Avulsion of the hamstring muscle group: a follow-up of 6 adult non-athletes with early operative treatment: a brief report. *World J Surgery* 2009; 33:1605-1610.
20. Miller SL, Gill J, Webb GR. The proximal origin of the hamstrings and surrounding anatomy encountered during repair. A cadaveric study. *J Bone Joint Surg Am* 2007; 89A: 44-48.
21. Orava S, Kujala UM. Rupture of the ischial origin of the hamstring muscles. *Am J Sports Med* 1995; 23: 702-705.
22. Puranen J, Orava S: The hamstring syndrome. A new diagnosis of gluteal sciatic pain. *Am J Sports Med* 1988; 16:517-521.
23. Sallay PI, Friedman RL, Coogan PG, et al. Subjective and functional outcomes following surgical repair of complete ruptures of the proximal hamstring complex. *Orthopedics* 2008; 31:1092-1096.
24. Sarimo J, Lempainen L, Mattila K. Complete proximal hamstring avulsions: a series of 41 patients with operative treatment. *Am J Sports Med*; 2008; 36:1110-1115.
25. Zissen MH, Wallace G, Steven KJ, et al. High hamstring tendinopathy: MRI and ultrasound imaging and therapeutic efficacy of percutaneous corticosteroid injection. *Am J Roentgen*; 2010; 195:993-998.