Hip Arthroscopy Techniques:

Deep Gluteal Space Access

Carlos A. Guanche, MD
Southern California Orthopedic Institute

6815 Noble Avenue

Van Nuys, CA 91405

cguanche@scoi.com

Abstract

With the expansion of endoscopically exploring various areas around the hip, have come new areas to define. The area posterior to the hip joint, known as the subgluteal space or deep gluteal space (DGS), is one such area. This chapter will summarize the relevant anatomy and pathology commonly found in the DGS. It is hoped that this will the reader to further explore the area and treat the appropriate pathological areas.

Key Words: Deep Gluteal Space Sciatic Nerve Piriformis Syndrome

Arthroscopy Techniques: Deep Gluteal Space Access

Introduction

With the increasing abilities gained in exploring various areas endoscopically has come an expansion of what can be explored. The area posterior to the hip joint, known as the subgluteal space or deep gluteal space (DGS), is one such area. It has been known for many years that there is a significant cohort of patients that have persistent posterior hip and buttocks pain, whose treatment has been very difficult. Part of the difficulties have stemmed from poor understanding of the anatomy and pathology of this area. With endoscopic exploration of DGS, orthopedic surgeons have been able to visualize the pathoanatomy, and therefore, have a better understanding of the pathologies in a part of the body that has been historically ignored.

The complexity of the area makes diagnosis difficult, as there are osseous, vascular, neural and muscular elements to the pathological processes in the space. The anatomy is intricate and the pathological processes are poorly understood, with only small case series available in the literature.(1, 2) The primary goal of this chapter is to serve as a baseline description for access and exploration of the deep gluteal space. Some of the common entities encountered will also be briefly discussed.

Anatomy of Deep Gluteal or Subgluteal Space

The DGS is the posterior extension of the peritrochanteric space and is largely the potential space deep to the gluteus maximus muscle. More specifically, the posterior border of the space is the anterior surface of the gluteus maximus with the distal margin beginning inferiorly at the femoral insertion site of the gluteus maximus tendon on the linea aspera and proximal margin at the origin of the gluteus maximus on the iliac crest. Anteriorly, the space is bordered by the sacrotuberous and falciform fascia medially, and the ischium, hamstring origin, and the inferior margin of the sciatic notch laterally.(3) Finally, the posterior femoral neck is the most lateral portion.(Figure 1)

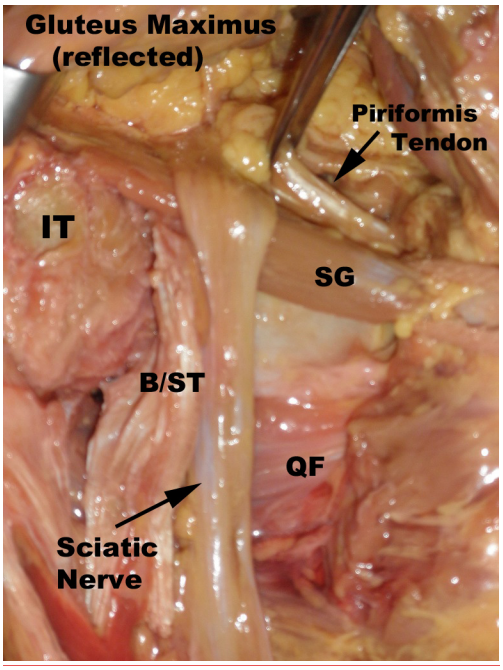

The contents of the space include the sciatic nerve, piriformis, obturator internus/externus, the gemelli, quadratus femoris, hamstrings, superior and inferior gluteal nerves, lateral ascending vessels of the medial femoral circumflex artery, the ischium, the sacrotuberous and sacrospinous ligaments and the origin of the ischiofemoral ligament.

Some specifics of the anatomy are critical to understanding the pathological processes that are encountered within the space. From the sciatic notch, the piriformis muscle originates from the ventrolateral surface of the sacrum and courses between the iliotibial band and inserts on superior and posterior aspect of the greater trochanter.(Figure 1) Distal to the piriformis is the cluster of short external rotators: the gemellus superior, obturator internus, and gemellus inferior.(Figure 2)

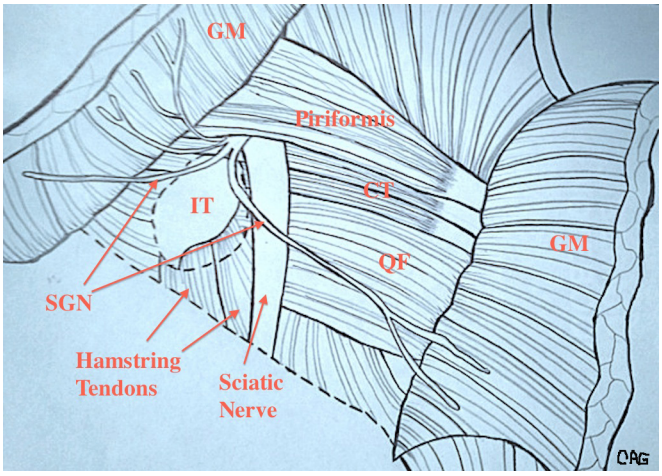

The gemelli blend with the obturator internus onto the anterior aspect of the medial surface of the greater trochanter.(3) The piriformis tendon can be partially blended with this common tendon in its insertion.(4) The obturator internus arises from the inner surface of the anterolateral wall of the pelvis and exits the pelvis through the lesser sciatic foramen. The superior gemellus arises from the outer surface of the ischial spine and the inferior gemellus arises from the ischial tuberosity. Inferior to this complex is the quadratus femoris, which arises from the upper part of the external border of the ischial tuberosity and inserts on the posterior surface of the femur, along the intertrochanteric ridge. The quadratus assists in external rotation, while the piriformis and short external rotators assist external rotation and abduction of the flexed hip. At the ischium, the

biceps femoris and semitendinosus have a common tendinous origin that separates about nine cm from the proximal border of the origin. (5)(Figure 3)

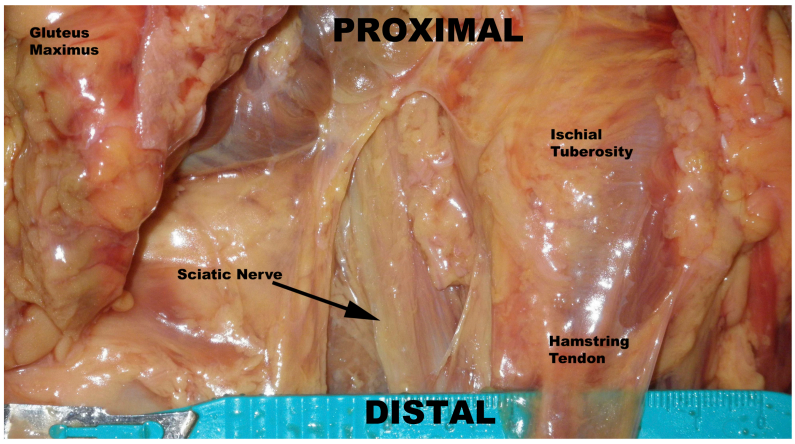

Figure 3

Six neural structures exit the pelvis through the greater sciatic notch. The neural structures include the sciatic, pudendal, posterior femoral cutaneous, superior gluteal, inferior gluteal nerves and the nerve to the obturator internus. In addition the superior and inferior gluteal arteries also exit through the greater sciatic notch. The sciatic nerve courses distally through the space anterior to the piriformis muscle and posterior to the obturator/gemelli complex as well as the quadratus femoris. There are, however, a number of anomalies that are commonly encountered that include entry into the space either through or posterior to the piriformis. These have been documented in up to 17% of cases in several cadaveric studies.(6) The superior gluteal artery and nerve divide 1-2 cm above the superior border of the piriformis and fan out in a course anterior and distal to the greater sciatic foramen between the gluteus minimus and medius, supplying those muscles and the tensor fascia femoris.(7) The inferior gluteal nerve and artery enter the pelvis at the greater sciatic notch medial to the sciatic nerve between the piriformis and

coccygeus muscles.(3) It descends, along with the sciatic and posterior femoral cutaneous nerves, between the greater trochanter and the ischial tuberosity. Clinically, this nerve is found penetrating the gluteus maximus five cm above its inferior border.

The medial circumflex artery is also relevant within the space. If follows the inferior border of the obturator externus and crosses over its tendon and under the external rotators and piriformis muscle. This vessel terminates as the lateral retinacular vessels, which are the principal blood supply of the femoral head in adults.

The sciatic nerve is located at an average of 1.2 ± 0.2 cm from the most lateral aspect of the ischial tuberosity. Under normal conditions, the sciatic nerve is able to stretch and glide to accommodate strain or compression that occurs with hip motion. One study has documented that with a straight leg raise and knee extension, the sciatic nerve experiences a proximal excursion of 28 mm medial toward the hip joint.(8) Any entrapment of the nerve, therefore, may increase the likelihood of decreased translation of the tissues and subsequent development of pain in the nerve's distribution. Sources of sciatic nerve entrapment include hamstring tendon disruptions and their consequent scar formation immediately adjacent to the nerve. The piriformis tendon is also commonly implicated in compression of the nerve. In addition, malunited ischial avulsion or lesser trochanteric fractures can lead to perineural scar formation. Other etiologies include vascular anomalies, tumors as well as the gluteus maximus tendon in cases of prior iliotibial band releases. Remote acetabular fractures can also lead to nerve impingement.

One other source that is starting to be understood is ischiofemoral impingement. The disorder has been described in the radiological literature, to some extent.(9, 10, 11) The mechanism is that of entrapment of the nerve between some portion of the posterior femur and the ischium. The anatomy of this space makes it susceptible to impingement as the clearance between the structures is minimal, especially at the extremes of motion.(Figure 4)

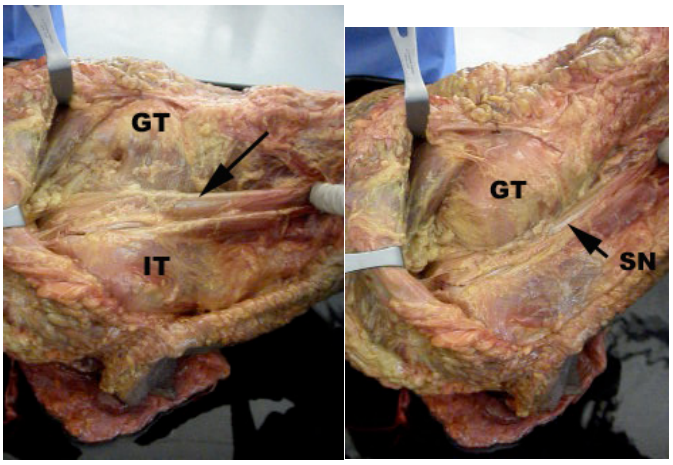

Figure 4A Figure 4B

In some cases, the quadratus femoris is hypertrophied and surgical release is indicated. As well, the lesser trochanter, lying underneath this muscle may be prominent. Care must be taken during the release of this muscle, as the medial circumflex femoral vessels are within the surgical field. It is vitally important not to compromise these, since they are the primary blood supply to the femoral head, as stated previously.

Surgical Technique

In most cases, the procedure is performed in the supine position and may be performed concomitant to a hip arthroscopy of the central and/or peripheral compartments, if indicated. The procedure is performed with the 30º arthroscope. In some cases, however, it is useful to employ the 70º device for added visualization. It is also possible to require the use of a longer arthroscope (probably a 70º device) in larger patients. The procedure can also be performed in the lateral position with the leg in a slightly abducted position.(Figure 5)

This is done in cases where there is no central or peripheral compartment pathology that needs to be addressed.

In the supine position, following the completion of the central and peripheral work, any traction is discontinued and the leg is abducted to about 30º in order to open the interval between the trochanter and the iliotibial band. The leg is internally rotated, for the same reason. Entrance into the subgluteal space is accomplished by traveling through the peritrochanteric space, which is between the greater trochanter and the iliotibial band. A modified anterior (MA) portal, which has been used for anterior visualization of the

central and peripheral compartments, is used to enter the peritrochanteric space between the tensor fascial femoris (laterally) and the rectus femoris (medially).(1)(Figure 6)

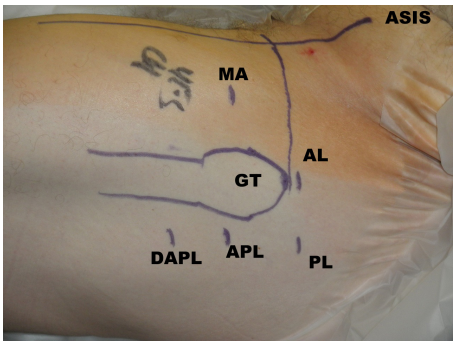

This is accomplished by palpating the interval between these two muscle bellies with the blunt arthroscopic probe and cannula. Ultimately, the space is successfully entered when the lateral aspect of the greater trochanter is palpated and can be confirmed with the use of fluoroscopic guidance. An anterolateral (AL) portal is then employed as a working portal in the trochanteric bursa. The procedure then continues by exposure of the bursa and resection of abnormal bursal tissue, as necessary.(Figure 7)

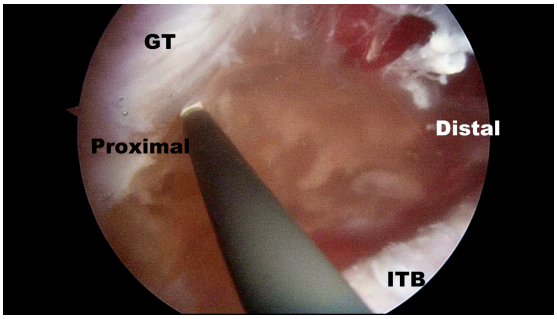

Once the peritrochanteric space is cleared and any encountered pathology is addressed, the more posterior aspect is identified and the subgluteal space is formally entered. With respect to orientation, a predictable technique is to place the arthroscope perpendicular to the patient and look in a distal direction in order to identify the gluteus maximus tendon

inserting into the linea aspera of the femur posteriorly. (Figure 8)

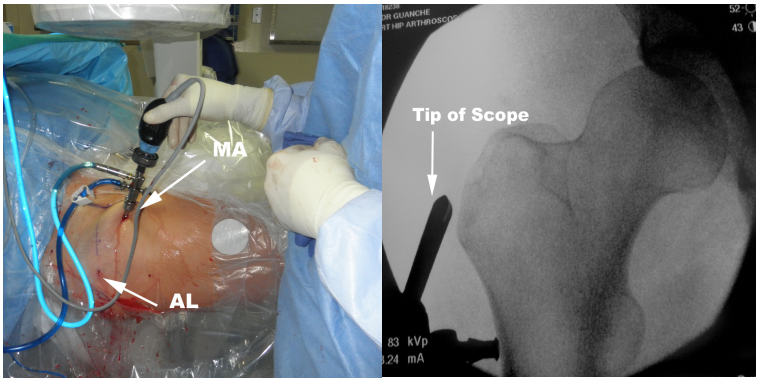

Figure 8A Figure 8B

Once this structure is identified the area of the sciatic nerve can then be known. It lies directly posterior to this structure as it exits the subgluteal space.(Figure 9)

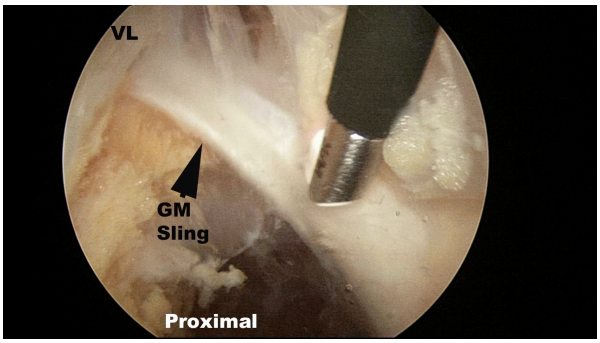

In most cases, an auxiliary posterolateral (APL) portal is created about three cm posterior to the posterior aspect of the greater trochanter. This serves as a further working portal, while continuing to visualize from the anterior (MA) portal. In some cases, it is necessary to establish an additional, more distal portal for more posterior visualization around the greater trochanter and towards the piriformis. This portal, termed the distal auxiliary posterolateral (DAPL), is created in parallel with the APL and is about four cm distal to that portal.(Figure 6)

The primary area of interest in most of these cases is the sciatic nerve. Secondarily, the area of the hamstring origin can also be a source of pathology and is certainly part of this space. However, a separate chapter is this book serves to describe a more effective way to address primary hamstring and ischial pathology (which includes that the patient be positioned prone).

As previously stated, the nerve is known to be immediately posterior to the gluteal sling so that it can be traced proximally from that point. Inspection of the sciatic nerve then begins distal to the quadratus femoris, just above the gluteal sling. A blunt probe or surgical dissector can then be employed to expose the sciatic nerve and any vascular scar bands over the quadratus femoris and the conjoint tendon of the gemelli and obturator internus. Finally, the piriformis muscle is identified, and any abnormal anatomical variants are identified. In cases where a piriformis nerve release will be performed, the muscle belly is followed laterally into its insertion into the apex of the greater trochanter.(Figure 2) The tendon is typically confluent with the common tendon and must be separated from that structure in order to completely release it and allow medial

retraction of the belly of the muscle.(Figure 10)

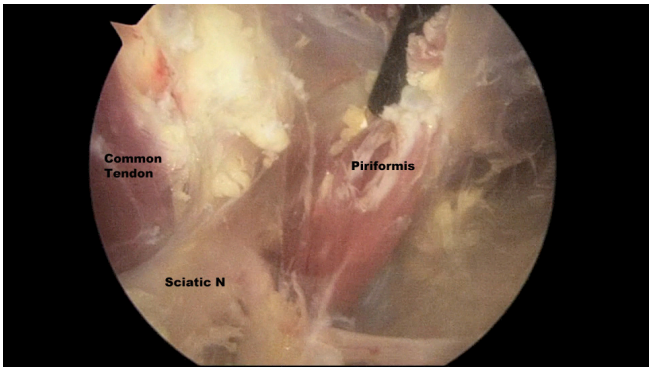

It is important to assess the sciatic nerve for its mobility prior to beginning any surgical dissection. With the arthroscope visualizing the nerve, the hip can be flexed and rotated in any direction in order to assess not only the mobility, but also for any evident impingement. This can occur anywhere along the posterior aspect of the femur (from the greater to the lesser trochanter) and also against the ischium and hamstring.(Figure 11)

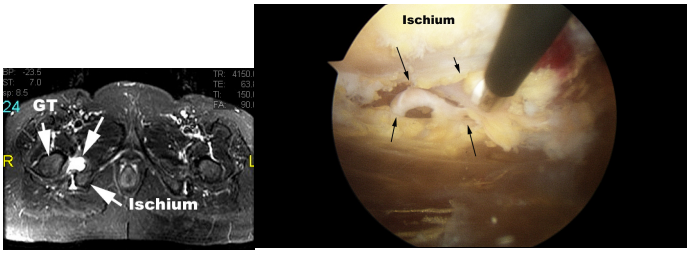

Figure 11A Figure 11B

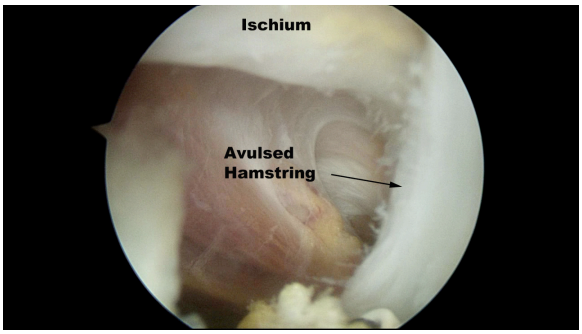

Figure 11C

Following decompression of the nerve, an assessment of the nerve mobility can be done by repeating the active hip motion assessment.(Figure 12)

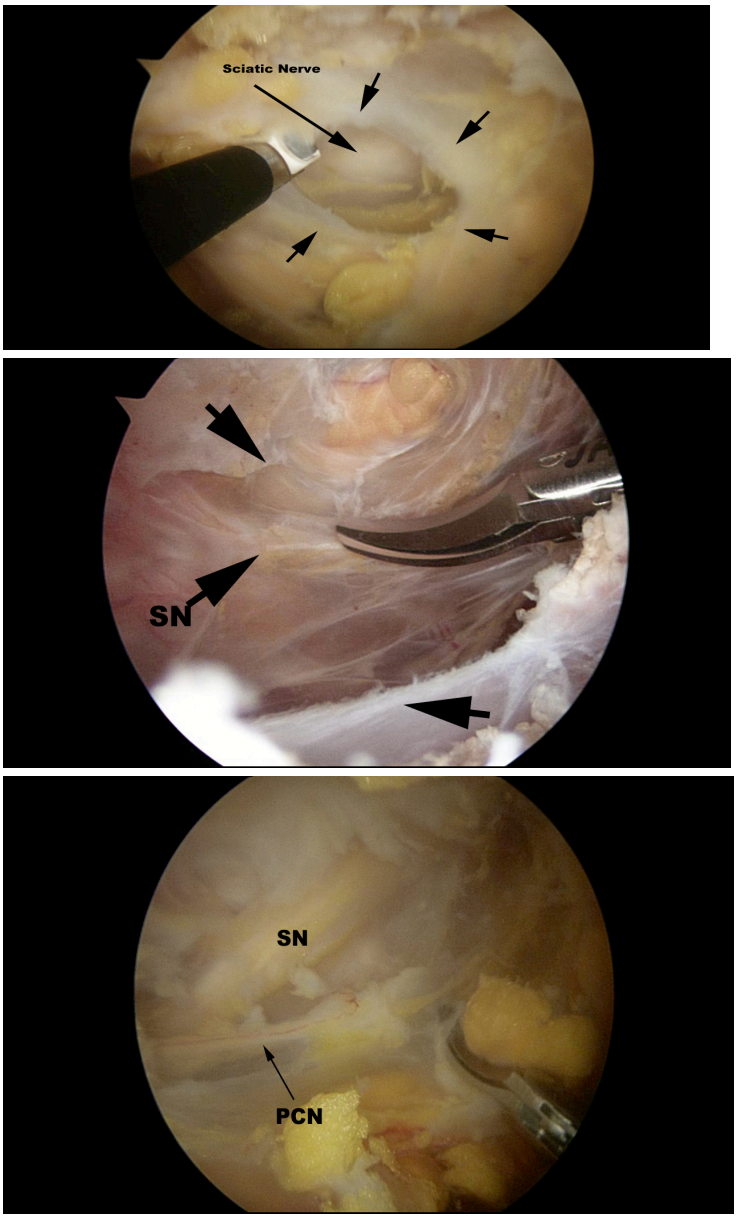

In general, all of the structures along the course of the sciatic nerve have been implicated as causative factors in chronic sciatic symptoms.(1) The findings by Martin, et al, included adhesions over the ischium posteriorly and inferiorly, multiple sciatic nerve branches with multiple branches encased in scar tissue, adhesions of the nerve lateral to ischium with no excursion, and a hypovascular appearance in some nerves. Interestingly, 27 patients in the their study had greater trochanteric bursal adhesions that were excessively thickened and appeared to extend to near the sciatic nerve. They also found the sciatic nerve entrapped by the piriformis tendon in 18 patients. Characteristics of the piriformis muscle included splits of the muscle in several cases. (1)

Most of the time, a blunt dissector, such as a switching stick, can be employed for release of scar bands. It is recommended that arthroscopic dissection scissors also be available for the dissection of finer tissues that are more adherent to the nerve. (Figure 12) Fibrovascular tissue can also be cauterized with a radiofrequency probe. Constant attention must be paid to the branches of the inferior gluteal artery lying in proximity to the piriformis muscle, as these are critical to the blood supply of the femoral head.(1)

One aspect that needs to be taken into consideration is the potential complications in that may occur in the DGS and the lack of historical knowledge of the pitfalls in the treatment of these entities. The most obvious issue is damage to the sciatic nerve. Clearly, this is a critical structure to the function of the entire lower extremity and damage to it can cause innumerable complications as it relates to function of the extremity. The role of devascularization of the nerve following surgical dissection needs to be evaluated and

parameters need to be established with respect to that issue.(1)

Another area that deserves special mention is abdominal (retroperitoneal) fluid extravasation.(Figure 13)

This is monitored by maintaining fluid inflow at a minimum pressure that allows good visualization, along with the use of hypotensive anesthesia, when not clinically contraindicated. Other safeguards include the regular monitoring of the patient for any obvious signs of fluid distension as well as the continued awareness of any decrease in body temperature while being monitored by the anesthesia team.(12)

Summary

As a result of the expanding interest in hip arthroscopy and more generally, hip pathologies, this area is a recently defined anatomic region that is very amenable to endoscopic access and evaluation. Currently, the techniques available are limited by the lack of insight into the pathologies that are present and how to effectively treat them. However, there is an explosion of knowledge that is taking place as it relates to the diagnosis and treatment of the entities in this space. Further refinement in the diagnosis and management of deep gluteal space pathologies will certainly be seen in the future.

The further improvement of these procedures will most certainly provide a less invasive approach for disorders presently addressed with major open procedures. While conventional open techniques can also address these pathologies, the use of the magnification inherent to arthroscopy adds significant value to any procedure performed in that space, given the delicate nature of the structures contained as well as less overall morbidity. Finally, there is sure to be an expansion of procedures to address some of these previously hard to define disease entities, leading to overall better care of these complex patients.

References

1. Martin HD, Shears SA, Johnson JC, Smathers AM, Palmer IJ. The endoscopic treatment of sciatic nerve entrapment/deep gluteal syndrome. Arthroscopy. 2011; 27:172–181.

2. Dezawa A, Kusano S, Miki H. Arthroscopic release of the piriformis muscle under local anesthesia for piriformis syndrome. Arthroscopy. 2003;19: 554–557.

3. Guvencer M, Akyer P, Iyem C, Tetik S, Naderi S. Anatomic considerations and the relationship between the piriformis muscle and the sciatic nerve. Surg Radiol Anat. 2008;3 0:467–474.

4. Meknas K, Christensen A, Johansen O. The internal obturator muscle may cause sciatic pain. Pain. 2003; 104: 375–380.

5. Miller SL, Webb GR. The proximal origin of the hamstrings and surrounding anatomy encountered during repair. Surgical technique. J Bone Joint Surg Am. 2008; 90 (Suppl 2 Pt 1):108–116.

6. Smoll NR. Variations of the piriformis and sciatic nerve with clinical consequence: a review. Clin Anat. 2010; 23: 8–17.

7. Jacobs LG, Buxton RA. The course of the superior gluteal nerve in the lateral approach to the hip. J Bone Joint Surg. 1989; 71:1239–1243.

8. Coppieters MW, Alshami AM, Babri AS, Souvlis T, Kippers V, Hodges PW. Strain and excursion of the sciatic, tibial, and plantar nerves during a modified straight leg-raising test. J Orthop Res. 2006; 24:1883–1889.

9. Miller A, Stedman GH, Beisaw NE, Gross PT. Sciatica caused by an avulsion fracture of the ischial tuberosity. A case report. J Bone Joint Surg. 1987; 69:143–145.

10. Patti JW, Ouellette H, Bredella MA, Torriani M. Impingement of lesser trochanter on ischium as a potential cause for hip pain. Skeletal Radiol. 2008; 37:939–941.

11. Torriani M, Souto SC, Thomas BJ, Ouellette H, Bredella MA. Ischiofemoral impingement syndrome: an entity with hip pain and abnormalities of the quadratus femoris muscle. Am J Roentgenol. 2009; 193:186–190.

12. Kocher MS, Frank JS, Nasreddine EY, Safran MR, Philippon MJ, Sekiya JK, Kelly BT, et al. Intra-abdominal fluid extravasation during hip arthroscopy: a survey of the MAHORN group. Arthroscopy. 2012; 28: 1654-1660.

Figures

Figure 1: The borders of the subgluteal space.

A. Cadaveric dissection of a right subgluteal space, visualized from posterior. Note the entrance of the sciatic nerve just below the piriformis tendon and lying on the common tendon. (B/ST: Common tendon of Biceps and Semitendinosus that has been partially detached and slightly everted; IT: Ischial Tuberosity; QF: Quadratus Femoris)

B. A diagrammatic representation of a right subgluteal space. (CT: Conjoint tendon of the superior and inferior gemelli, along with the obturator internus; GM: Gluteus maximus muscle, everted; IT: Ischial Tuberosity; QF: Quadratus Femoris)

C. An axial, T1 weighted image of a right hip. The yellow line outlines the borders of the space. (SN: Sciatic Nerve; P: Piriformis muscle; GT: Greater Trochanter; GM: Gluteus Maximus

Figure 2: The sciatic nerve (SN) resting on the common tendon and exiting below the piriformis (Arrows). (OI: Obturator Externus; SG: Superior Gemellus

Figure 3: The lower portion of the deep gluteal space. (View is of a left hip, from the posterior aspect.)

Figure 4: Ischiofemoral impingement in a cadaver. The view is of a right hip and the proximal portion is to the left.

A. With the leg in neutral rotation that is space between the trochanter (GT) and the ischium for the sciatic nerve SN) to glide.

B. With external rotation, there is a diminished space between the GT and the Ischium (IT)

Figure 5: Positioning for access to the deep gluteal space in the lateral position. Note the leg is abducted about 30º.

Figure 6: The typically employed portals for access to the deep gluteal space in a left hip. (Note: the leg is to the left) (AL: Anterolateral portal; MA: Modified anterior portal; APL: Auxiliary Posterolateral portal; DAPL: Distal Auxiliary Posterolateral portal; GT: Greater Trochanter; ASIS: Anterior Superior Iliac Spine)

Figure 7: Visualization of the greater trochanteric bursa in a right hip, with the distal aspect to the right. The visualization portal is the MA and the instrument is being inserted via the AL portal. (GT: Greater trochanter; ITB: Iliotibial Band)

Figure 8: Appropriate position of the arthroscope in a right hip in order to locate the gluteal sling. The camera is positioned parallel to the body and the scope is visualizing distally.

A. Distal visualization allows one to identify the gluteal sling for orientation. Note visualization is from the modified anterior (MA) portal and the working portal is the anterolateral (AL) portal.

B. Fluoroscopic view of the arthroscope in the right trochanteric bursa.

Figure 9: The gluteal sling in a right hip. Note the fatty tissue immediately posterior to the sling, where the sciatic nerve resides. (VL: Vastus lateralis; GM sling: Gluteus maximus sling)

Figure 10: Piriformis release for sciatic nerve entrapment in a left hip. Note, this is the release of the tendon previously seen in figure 2.

Figure 11: Ischiofemoral impingement in a right hip.

A. Axial, T2 weighted MRI showing fluid in the interval between the ischium and the greater trochanter. The arrow is indicating the fluid collection between the greater trochanter and the ischium. (GT: Greater Trochanter)

B. Visualization of the area of hamstring impingement. The arrows indicate the rent in the hamstring sheath. The sciatic nerve is immediately posterior in the visualized fatty tissues.

C. With retraction of the rent in the sheath, the deep avulsion of the tendon can be seen.

Figure 12: Dissection of sciatic nerve scar tissue in a patient with ischiofemoral impingement. This is a right hip procedure.

A. Visualization, via the DAPL and working via the PL portal. The arrows are pointing to the areas of scar tissue with the sciatic nerve in the depths of the field.

B. With resection of some of the scar tissue, the sciatic nerve is more obvious within the field of view. The arrows are pointing to scar that is being resected. (SN: Sciatic Nerve)

C. The completed nerve decompression. The sciatic nerve (SN) is clearly seen as well as the posterior cutaneous nerve (PCN) that runs parallel to the sciatic, slightly more posteriorly.

Figure 13: Case of abdominal extravasation. CT scan of a patient who underwent a decompression of the sciatic nerve in the supine position. Examination at the end of the procedure revealed a significant amount of abdominal distension. The CT examination revealed the extent of the fluid extravasation in the retroperitoneal space (arrows are pointing to areas of diffuse extravasation) with displacement of the abdominal contents anteriorly (yellow line indicates the posterior and inferior extent of the displacement of the abdominal contents).