15 SHOULDER: CARTILAGE

CARLOS A. GUANCHE, MD

KEY POINTS

- Full-thickness articular cartilage defects have a limited capacity to heal. Thus, articular cartilage lesions and osteochondral defects in any joint present a challenging problem.
- Cartilage lesions are less likely to be seen in the glenohumeral joint than in the knee, therefore there has not been extensive research on shoulder cartilage repair.
- Making the diagnosis without the benefit of an arthroscopic visualization of the joint can be problematic.
- Mechanical injuries include direct trauma to the cells and matrix, causing an acute disruption of the surface, or more subtle changes attributable to damage of the matrix macromolecules.
- Biologic injuries include metabolic abnormalities, most commonly osteoarthritis, but also avascular necrosis and a variety of osteochondral injuries.
- Although the use of gadolinium-enhanced arthrograms has improved diagnosis, a significant portion of lesions are not identified prospectively.
- The goal of treatment is often to restore durable hyaline cartilage through a practical and minimally invasive approach (preferably arthroscopic), which is associated with minimal morbidity postoperatively and in the long term.
- The end-stage management of many cartilage lesions is a replacement procedure. A titanium coated shaft portion with an articular bearing surface of cobalt-chrome alloy is implanted in the central articular defect and recreates the circumference of the humerus.
- The goals of arthroscopic debridement are primarily to relieve pain and secondarily to improve function. The removal of loose tissues that cause pain and impingement helps to achieve these goals.
- The decision making process for arthroscopic debridement is radiographic analysis. The proper views are critical to allow an appropriate diagnosis. These include an anteroposterior (AP) view in internal rotation, an AP view in the scapular plane with the arm in external rotation and slight abduction and an axillary view.

INTRODUCTION

Articular cartilage lesions and osteochondral defects in any joint present a challenging problem to both patient and physician. The critical issue is that full-thickness articular cartilage defects have a limited capacity to heal at any age. Many procedures have been described to improve the joint alignment, induce reparative tissue proliferation or provide cartilage tissue that is more nearly normal. The bulk of this work has occurred in lesions about the knee, with very little research in any other joints. The use of autogenous and allograft reconstruction of focal defects has been extensively studied in the knee (1–3). Other techniques including abrasion arthroplasty, drilling, and microfracture have been described for smaller lesions (4–6). There is a paucity of research that discusses the problem of cartilage lesions about the glenohumeral joint and provides treatment recommendations, with the exception of a few case reports and small series of patients.

Certainly, the problem is less likely to be seen about the glenohumeral joint and therefore impacts the lack of need for extensive research. Complicating the problem is that unlike the knee, there is significant difficulty with access to the joint when a lesion is identified. Furthermore, the management options are not as obvious as a result of the lack of large-scale research.

There is a spectrum of pathology encountered with the lesions ranging from simple chondral delamination injuries to more extensive osteochondral injuries and culminating in arthritic degeneration of the glenohumeral joint. All of these lesions can be encountered in the typical active population commonly seen in the average sports medicine practice.

Making the diagnosis can also be problematic without the benefit of arthroscopic visualization of the joint. Several series point to the need for improved imaging techniques that allow better determination of the articular surfaces in a prospective fashion and this area also requires further study (7,8). In addition, the concurrent association of cartilage defects with the status of other areas of the joint, specifically, the rotator cuff and impingement is poorly understood both with respect to etiology and treatment (9,10).

After the diagnosis has been made, there are many options available for treatment if the management algorithms follow those historically applied to knee pathology. There are a variety of autogenous techniques including osteoarticular harvest with subsequent transplantation as well as the more complex technique of biologic regeneration of cartilage (2). Allograft applications are also available and those include fresh and preserved specimens. In addition to the biologic resurfacing techniques, there are also devices that allow for resurfacing using metallic and other materials. Finally, in cases of limited damage or sometimes in the face of extensive degeneration of the cartilage surfaces, arthroscopic techniques can be employed primarily for symptom amelioration (9,11–13).

IMPACT OF CARTILAGE LESIONS

The spectrum of pathology includes a gradation in the severity of cartilage damage beginning with simple delamination of a small area and ending with complete degeneration of the articular surfaces, i.e., osteoarthritis.

Although the glenohumeral joint surface geometry historically has been considered less of a stabilizing factor as a result of the smaller surface area of the glenoid in comparison with the humeral head and the apparent shallowness of the glenoid, technology has now given us a new perspective. Classically, most studies of the joint have analyzed congruency with radiographs, thus underestimating the degree of congruity afforded by the articular cartilage because only the bony surfaces were visualized and assessed (14). If only the subchondral bone is analyzed, there appears to be less conformity within the joint. With the addition of the articular cartilage, the effective congruence of the joint is much greater.

As an example, Kelkar et al. (14) analyzed a group of glenohumeral cadaveric joints. In their analysis, the average radii of the humeral head and glenoid articular surfaces were 25.5 and 27.2 mm, respectively. The average difference between the two radii was 1.7 ± 1.5 mm. When the same technique was employed to analyze the subchondral bone, the radii of curvature of the humeral heads and glenoids were 25.2 and 33.4 mm, respectively. These findings lend more importance to the articular cartilage, or more specifically the preservation of this tissue. It appears that the articular cartilage of the glenohumeral joint is a factor in the maintenance of stability in the joint. Given the inherently unstable nature of the joint with its small surface area, it is paramount to save as much cartilage as possible in order to preserve normal joint function.

Another consideration is the impact of associated coexistent disease processes in the shoulder. More importantly, focal articular lesions are often found incidentally at the time of arthroscopic evaluation of the joint for other presumptive diagnoses. This problem has been seen less frequently as a result of the improvements made in prospective diagnosis with the use of MRI techniques, particularly those employing gadolinium-enhanced arthrograms.

Several studies allude to the coexistence of other disease processes with cartilage lesions, however, especially more advanced lesions seen with osteoarthritis (8,9,10). In their study, Feeney and colleagues assessed 33 cadaveric shoulder joints and documented the incidence of rotator cuff tearing and cartilage lesions (10). Articular cartilage degeneration was almost twice as frequent in the group with rotator cuff tears as in those without tearing (10).

Another study revealed that in a series of 52 patients undergoing surgery for subacromial impingement syndrome, humeral cartilage lesions were found in 29%, of which four lesions were subtle and eleven were marked (9). In the glenoid, 15% were found to have lesions with three subtle and five marked. In essence, patients with clear surgical indications for impingement surgery may have coexistent cartilage lesions in up to one third of instances. This consideration should be taken into account at the time of preoperative discussion with the patient, as other procedure may be essential for complete treatment.

Types of Lesions

Cartilage repair response has been the focus of investigations for more than 250 years. In 1742 Hunter noted that "ulcerated cartilage is a troublesome thing . . . once destroyed it is not repaired (15). Since that time, the observations made by Hunter have been reiterated by nearly every scientific study on the topic. The lack of predictability of repair of cartilage is attributable to the many factors that often come together in a specific injury. Some of the factors include the precise injury, the age of the individual, the condition of the joint before injury, the quality, extent, and durability of the repair and the long-term function of the joint.

The types of injuries can be divided into mechanical and biologic. The mechanical types of injuries include direct trauma to the cells and matrix causing an acute disruption of the surface, or more subtle changes attributable to damage of the matrix macromolecules. This type of damage occurs with surgical disruption of the synovial membrane, infection

and other inflammatory diseases, immobilization and possibly joint irrigation (15).

In cases of blunt injury, the degree of disruption is often underestimated in the acute phases. The response of articular cartilage to penetrating injury depends on the depth of injury such that injuries limited to cartilage elicit a different repair response than injuries involving cartilage and subchondral bone. Likewise, blunt trauma can have much more significant impact than is acutely appreciated as a result of the consequent cell injury and effect on the cellular matrix, as well as any injury to the subchondral supporting bone (16).

The biologic injuries include metabolic abnormalities, most commonly osteoarthritis, but also avascular necrosis and a variety of osteochondral injuries that damage the articular layer indirectly as a result of the collapse of the supporting structures. For example, MRI analysis in degenerative joint disease, osteochondritis dissecans and avascular necrosis has shown that the subchondral region shows reactive enhanced vascularization and heightened metabolism with insufficient repair (17).

One particular disease process that deserves further mention is that of avascular necrosis because the humeral head is the second most common site of nontraumatic osteonecrosis, after the head of the femur (18). In humeral head osteonecrosis, subchondral osteolysis occurs in the superior portion. When resorption of subchondral bone is extensive, it appears that even ordinary forces transmitted across the joint will lead to subchondral fracture and humeral head collapse (18). The likelihood of this collapse and the consequent degenerative changes that would occur make this disease process one that must be addressed more expediently than other cartilage lesions.

The treatment of specific injuries is impacted by the underlying nature of the cartilage injury. The best outcomes are obviously in isolated lesions that have a clear, mechanical etiology without any underlying metabolic abnormalities. The discussion of the factors involved is beyond the scope of this chapter, but the reader is directed to the appropriate references (14,19,20).

Separate consideration should be given to osteoarthritis, as there are clear surgical indications in the treatment of the disease in the glenohumeral joint (without prosthetic replacement). The arthroscopic management of this problem, if performed in the appropriate patient, has been shown to provide significant improvement in symptomatology (11–13,21).

Diagnosis of Cartilage Lesions

Much effort has been directed at the development of imaging techniques that effectively diagnose cartilage lesions in the shoulder. The thrust of the research has employed a variety of magnetic resonance imaging techniques to delineate not only the actual lesions, but also something about their physiology. It is well established that cartilage functions as the load-bearing surface in the joints of the musculoskeletal system. Major macromolecules in cartilage are collagen Type II and proteoglycans. Although proteoglycans provide much of the compressive stiffness through electrostatic repulsion, collagen provides tensile and shear strength. Several studies have shown that the earliest stages of cartilage degeneration are primarily associated with loss of proteoglycan and minor changes in collagen structure (22). In one study, bovine articular cartilage was analyzed with a variety of MR parameters including T2 relaxation rates and spine-lattice relaxation times in the rotating frame ($T1\rho$) mapping method (23). The findings included a significant correlation between the changes seen on $T1\rho$ mapping and the sequential depletion of proteoglycan. Studies like these have served to expand the base of knowledge with regards to grading of articular lesions. Although arthroscopy is the so-called gold standard at this point for final determination of the management of these lesions, it would be ideal to have a non-invasive modality that fully assesses the lesions.

In the clinical setting, it is important to be able to delineate the presence of cartilage lesions with some certainty. There are several studies available in the literature that gives some guidance (7,8,24). In one study, a double blind prospective study of 15 patients with anterior shoulder instability were analyzed with respect to the efficacy of MRI versus arthroscopy in the evaluation of chondral or osteochondral lesions of the humeral head (24). MR produced 6 true positives, 5 true negatives, and 4 false negatives for an accuracy and sensitivity of 60% and 87%, respectively. Arthroscopy gave 8 true positives, 5 true negatives, and 2 false negatives, with a sensitivity of 80% and an accuracy of 87%. All lesions diagnosed with either method were regarded as positive by definition, with the result that the specificity was always 100%. The differences in diagnosis sprang from the false negatives. As a result of the variable ability to identify the cartilage lesions prospectively, it was advised that both of these methods should be employed to ensure the correct diagnosis, and hence the correct choice of treatment.

Another study has described the MRI findings of focal articular cartilage lesion of the superior humeral head in seven patients (7). This was a retrospective study to evaluate the location and incidence of these lesions. The lesions occurred along the superior surface of the posterior humeral head (medial to the expected location of a Hill-Sachs lesion), were caused by trauma, and did not seem to have a specific mechanism of injury. It was felt that they may cause clinical symptoms and may be easily overlooked on MRI because they were missed on six out of seven of those encountered.

In the largest available study, Guntern et al. (8) determined the prevalence of articular cartilage lesions in a group of patients. Arthrographic images obtained in 52 consecutive patients with a mean age of 45.8 years were retrospectively evaluated for glenohumeral cartilage lesions. Two experienced musculoskeletal radiologists who were blinded to the arthroscopy report independently analyzed the articular cartilage. Humeral and glenoidal cartilage were assessed

separately and arthroscopic findings were used as the standard of reference. At arthroscopy, humeral cartilage lesions were found in 15 patients (frequency, 29%). Four lesions were subtle, and 11 were marked. Cartilage lesions of the glenoid were less frequent (eight patients; frequency, 15%): Three were subtle, and five were marked. For reader 1 and reader 2, respectively, sensitivity of MR arthrography for humeral cartilage lesions was 53% and 100%, specificity was 87% and 51%, and accuracy was 77% and 65%; sensitivity for glenoidal cartilage lesions was 75% and 75%, specificity was 66% and 63%, and accuracy was 67% and 65%. Interobserver agreement for the grading of cartilage lesions with MR arthrography was fair (humeral lesions, kappa = 0.20; glenoidal lesions, kappa = 0.27). Based on the study, it was felt that the performance of MR arthrography in the detection of glenohumeral cartilage lesions is moderate with a high degree of variability associated with the interpretation of the images.

As can be discerned by this analysis, much work needs to de done in the delineation of cartilage lesions on a prospective basis. While the use of gadolinium-enhanced arthrograms has clearly improved the ability to find these lesions, a significant proportion is not identified prospectively. Also, the biological parameters that are discernible with the use of MRI technology are important to consider. The ideal study that addresses not only the presence of a cartilage lesion, but also something about its biology or reparative capability is clearly within the grasp of modern imaging. Its implementation and refinement, however, await further studies.

TREATMENT ALTERNATIVES

In the past, the most common treatment for many if not most of the articular cartilage lesions that were seen in the shoulder (and other joints) was simple debridement and symptomatic management. Today's aim, however, is to restore durable hyaline cartilage through a practical and minimally invasive approach (preferably arthroscopic), that is associated with minimal morbidity perioperatively and in the long term.

There are several avenues available to accomplish the restoration of articular cartilage (1–3,25,26); however, most of the literature has been focused on knee joint abnormalities, with less attention to the other joints. The variety of techniques includes autogenous tissues, allograft tissues, and synthetic components.

In addition, simple debridement of the area of degeneration with subchondral stimulation is used on a routine basis (6). Although the use of this technique has not been explicitly studied in the literature with respect to the shoulder, the principles of stimulation of the subchondral area for creation of a fibrocartilaginous layer over the diseased area should also apply. This technique will be discussed in more detail in a later section of this chapter.

Autologous Tissues

The use of autologous tissues about the knee has been commonplace for several years, and has included the transplantation of local tissue, transfer of remote tissue, and finally the genetic production of cloned tissue from knee cartilage cells (1–3,27).

A technique that has been used in the knee is transfer of autologous tissue from other areas to reconstruct the articular cartilage, this technique has been termed mosaicplasty. Likewise in the humerus, the technique is certainly applicable. In one study, Scheibel et al. (28) have prospectively analyzed a series of autologous osteochondral plugs from the knee to the humerus in eight patients. The lesions were all Outerbridge grade IV and averaged 150mm^2. Standard radiographs, MRI, and second-look arthroscopy (in two patients) were used to assess the transplanted tissue. After a mean of 32.6 months MRI revealed good osteointegration and congruent articular cartilage in all but one patient. Second-look arthroscopy in two cases revealed good integration macroscopically with an intact articular surface. The Constant scores also increased significantly. The study certainly lends credence to the use of the procedure in the cases of limited lesions of the humeral head.

In cases where the lesion is larger or the availability of normal cartilage from another autogenous source precludes mosaicplasty, periosteal tissue has been employed (29). Basic science studies have shown that neochondrogenesis can be seen in animal models where a free autogenous periosteal graft is applied to full thickness articular cartilage lesions (30). Periosteum contains pluripotential mesenchymal stem cells with the cambium layer being responsible for many growth factors that regulate chondrocytes and cartilage development including transforming growth factor β_1, insulin-like growth factor 1 and others (31). In a limited series of patients, a tissue quite similar to articular cartilage was observed in the knee (32).

In the shoulder, a prospective series of five patients treated with an autogenous periosteal flap following microfracture of the defect has shown satisfactory short-term results (29). The technique included the use of the technique of Steadman et al. (6) where perforations into the subchondral bone at a distance of 3 to 4 mm between perforations were created. A periosteal flap harvested from the proximal humeral metaphysis (with the cambium layer facing the cartilage lesion) was then applied to the defect and sutured into place (33). The size of the defects in these patients averaged 311 mm^2 (range 225 to 400 mm). With a mean follow-up of 25.8 months, it was found that the Constant scores improved significantly from 43.4 to 81.8. Second look arthroscopy in three patients revealed a significantly reduced cartilage lesion. Follow-up MRI revealed that the area of the chondral defect was covered with a thin layer of regenerated cartilage tissue in all patients, but there were still signs of edema in the underlying subchondral bone plate. It was felt that this is a viable technique for larger defects not amenable to treatment with osteochondral plugs. Although the findings

did not show a completely normal cartilaginous surface, the authors were encouraged by the improvement in clinical symptomatology. Certainly, further follow-up is indicated in these patients before the technique can be espoused for most defects.

An additional autogenous technique that has been extensively analyzed with respect to the knee is that of autogenous chondrocyte implantation (ACI) (2,32). The technique involves the use of cells that are harvested from the articular cartilage surface, subsequently cultured in vitro, and reimplanted under a periosteal patch (2). In the shoulder, the technique has been reported in the form of a case report (34). The patient in this case sustained a lesion that, following preparation for the ACI procedure, measured 3.3 × 1.5 cm. At one year follow-up the patient demonstrated a full range of painless motion with no complaints of rest or weather change pain.

Allograft Tissues

Allograft tissues have been employed to reconstruct a variety of joint surfaces, and the humerus is certainly no different (35,36). The use of smaller focal defects, however, is not extensively described in the literature with the exception of a few case series. In one study, Gerber et al. (26) employed a large segmental humeral head allograft to reconstruct massive posterior humeral head defects (Hill-Sachs lesions) involving more than 40% of the articular surface. This treatise included four patients treated with the technique. It was found that stability was restored and maintained in each patient at an average of 68 months following the procedure. Three patients reported little or no pain and no or slight functional restrictions in activities of daily lining. One patient had mild pain and moderate-to-severe dysfunction secondary to avascular necrosis of the remaining portion of the humeral head. Although the technique appears to be worthwhile in this patient population, the use of this type of large allograft resurfacing in the more central portion of the humeral head may fare differently. The central humeral articular surface will experience significantly more mechanical stress compared to the peripheral humeral articular surface that was reconstructed with this technique.

Prosthetic Components

Obviously, the end-stage management of many of these cartilage lesions is a replacement procedure; however, in many situations the diseased portion is a limited area that is amenable to a limited replacement approach. Several devices are currently available, some experimental and some recently devised that allow for this limited resurfacing.

The currently available device is a titanium coated shaft portion with an articular bearing surface of a cobalt-chrome alloy (Arthrosurface; Franklin, MA). The device is implanted in the central articular defect either in an open or arthroscopic fashion and recreates the circumference of the humerus **(Fig 15-1)**. Several sizes of implants are available such that a circular defect up to 40 mm can be reconstructed. To date, there are no series of patients available that have been published in the peer-reviewed literature.

A variety of synthetic "articular cartilage-like" materials are also available. All of the devices are currently unavailable in the United States but are presently in use in some European countries and Japan. Again, the experience has been predominantly in the knee joint with an occasional series or case report in other joints such as the hip, ankle, or shoulder. The majority of the materials are hydrogels which are encapsulated and typically contain a suspension of saline with a variety of macromolecules that simulate the properties of articular cartilage (37). In a study evaluating the response normal cartilage to the hydrogels vs. aluminum and titanium implants in a rabbit model, there were marked pathologic changes noted on the knees with the harder implants, although the knees with the hydrogel implants had none to minimal changes (38). This supports some of the well-known literature on the use of hemiprosthetics in the shoulder and knee joint where degradation of the articular surfaces has been documented with long-term follow-up of these patients (39).

EARLY OSTEOARTHRITIS

Separate consideration should be given to the arthroscopic management of the early osteoarthritic shoulder. The disease in young patients is a challenging clinical problem. Nonsurgical treatment options include physical therapy, therapeutic modalities, intra-articular corticosteroid injections, activity modification, and non-steroidal anti-inflammatory medications (40). There is a substantial amount of literature to support the use of the arthroscope in these patients; however, the proper indications must be present to obtain good, predictable results. The routine use of the arthroscope for symptomatic relief of osteoarthritis is simply not substantiated in the literature.

Indications for arthroscopic debridement of shoulder osteoarthritis include young patients with early to moderate disease, preserved range of motion (>120 degree elevation, >20 degree external rotation at the side), concentric glenoid wear without evidence of subluxation, and minimal osteophyte formation (40,41).

In the athlete and young patient with osteoarthritis, arthroscopy allows recognition and treatment of coexisting pathologies in which procedures such as subacromial decompression and capsular release have proven to be of benefit. In fact, arthroscopy is the most sensitive method for diagnosing early osteoarthritis (9,42). Disorders such as rotator cuff tendinopathy, impingement syndrome, adhesive capsulitis, and biceps tendonitis often mimic osteoarthritis and are difficult to separate clinically. Through the use of arthroscopy, the proper diagnosis and specific treatment may be applied, thus maximizing the patient's opportunity for improvement **(Fig 15-2)**.

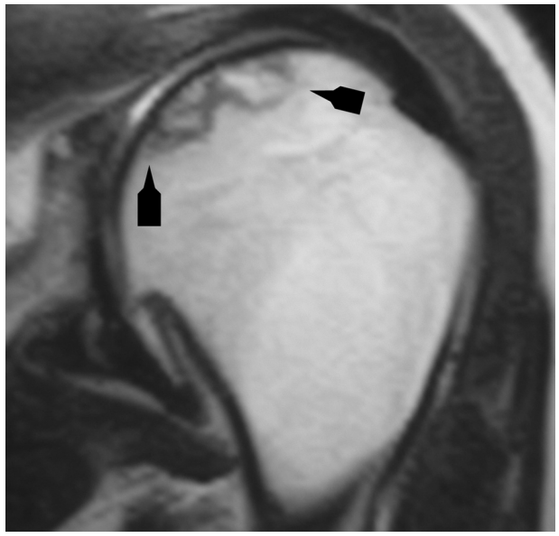

A

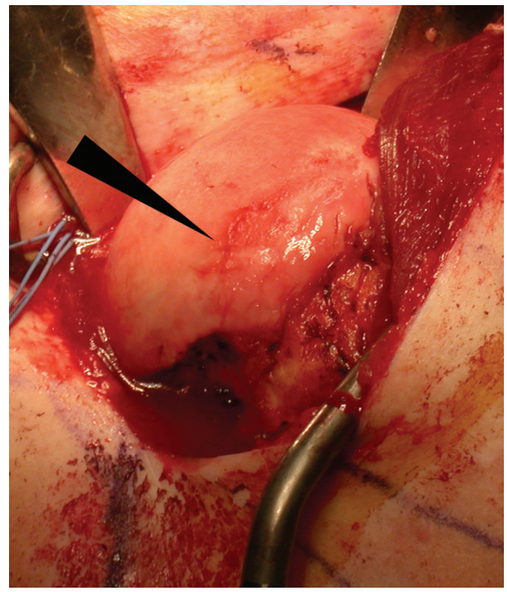

B

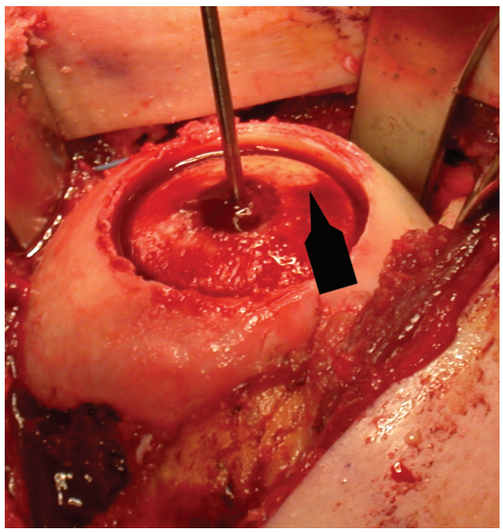

C

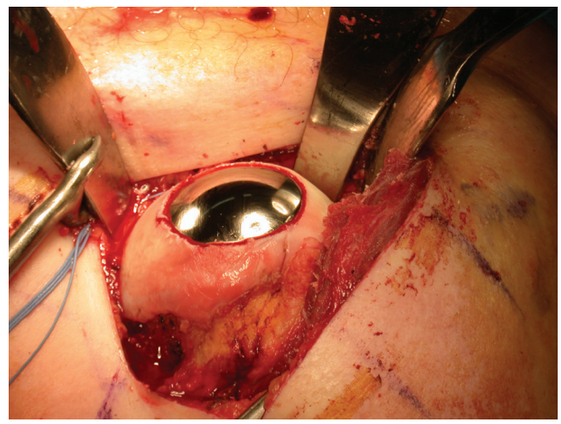

D

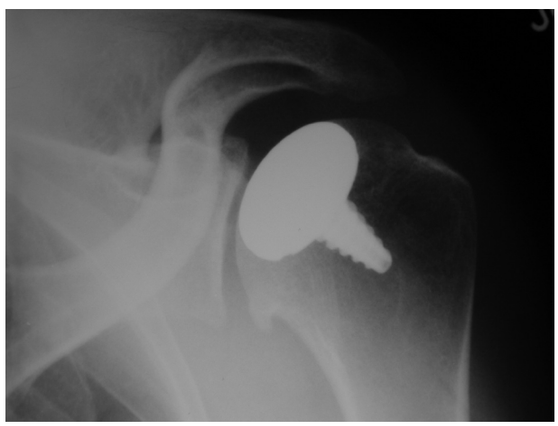

E

Fig 15-1. The use of a metal resurfacing device in the case of a 39-year-old patient with a history of avascular necrosis and consequent chondral damage secondary to subchondral collapse. **A:** MRI of avascular lesions (T1 weighted) depicting the area of diseased bone (arrows) over the superolateral head. **B:** Initial intraoperative view of chondral injury. **C:** Area of avascular bone visible (arrowhead) following reaming for resurfacing device. **D:** Final device implant in position (Arthrosurface). **E:** Final AP radiograph of resurfacing component in place.

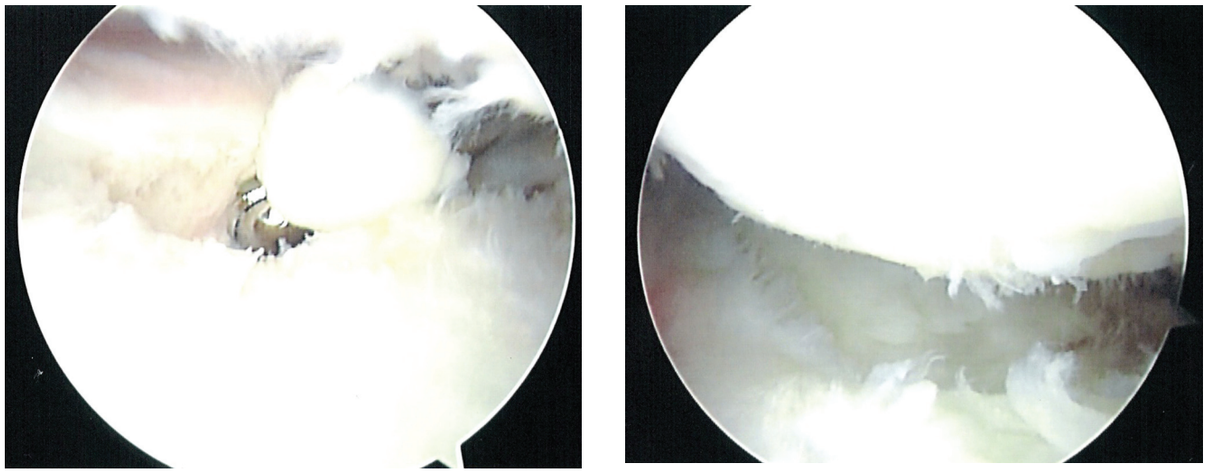

Fig 15-2. Thirty-two-year-old male with recurrent instability and now early osteoarthritic (grade A) changes radiographically. (Right shoulder viewed from posterior portal). **A:** Loose body in anterior glenoid-labrum junction. **B:** Humeral head articular changes.

The goals of arthroscopic debridement are primarily to relieve pain and secondarily to improve function. The removal of loose tissues that cause pain and impingement helps to achieve these goals. In some situations, the microfracture technique of subchondral bone perforation can be a useful adjunct in order to induce fibrocartilage formation over areas of exposed bone **(Fig 15-3)**. Although the technique has not been specifically analyzed with respect to the shoulder, there is certainly a substantial amount of literature to support its use in the knee with studies showing that it improves symptoms, reduces defect size, and allows earlier return to activity in patients with osteochondral defects (43) **(Fig 15-4)**. It should be kept in mind, however, that the duration of relief is highly variable and the procedure is at best a temporizing one (12,13,21). It can be highly advantageous, though, in the young active patient that desires to postpone prosthetic replacement.

An important component of the decision-making process for this procedure is radiographic analysis. The proper views are critical to allow an appropriate diagnosis and these include an anteroposterior (AP) view in internal rotation, an AP view in the scapular plane with the arm in external rotation and slight abduction and an axillary view (42). The scapular AP and the axillary view are the critical ones because they are orthogonal to the plane of the joint. To improve sensitivity, the AP view may be obtained with the patient in 45 degrees of abduction while contracting the deltoid. This procedure provides joint compressive force and helps delineate joint space narrowing that can be underrepresented in standard views (41). A useful classification system that is applicable to this patient population has been devised by Walch et al. (44). A Grade A lesion shows a centralized humeral head, Grade B has posterior subluxation of the humeral head, and grade C has a glenoid retroversion of >25 degrees. In this scheme, radiographic progression beyond a grade of A is a relative contraindication for arthroscopic debridement.

The typical arthroscopic debridement in these patients includes a thorough assessment of their motion and stability under anesthesia, as well as a thorough diagnostic arthroscopy including the subacromial space and the acromioclavicular joint (42).

An area that deserves particular mention is that of capsular release. In many of these patients, shoulder range of motion is significantly limited not only as a result of the degenerative changes, but also as a result of the capsular contractures that are often present. Certainly, part of the procedure would include a complete capsular release to improve the passive range of motion. The technique is described in other sections of this book, and the reader is directed to the appropriate references (12,42).

With regards to outcome, there are several studies in the literature that support the use of arthroscopy to improve the symptoms associated with degenerative shoulder joints (13,45–47). One study evaluated 25 patients at an average of 34 months follow-up (13). The overall results were rated as excellent in 2 patients, good in 19 patients, and unsatisfactory in 5 (20%). Two patients had complete pain relief and 18 had only occasional mild pain. Notably, of the 12 patients with marked stiffness preoperatively, 83% had improvement in range of motion. Of note in this population was the coexistence of significant intra-articular findings in 32% of the patients. This included labral tears, loose bodies, SLAP lesions, and partial cuff tears. Interestingly, there was no correlation between the radiographic grade and the clinical outcome.

Another study evaluated the results of arthroscopic debridement with or without capsular release in a group of sixty-one patients (12). At follow-up with 45 patients having a minimum of 2 years, 87% of patients indicated that

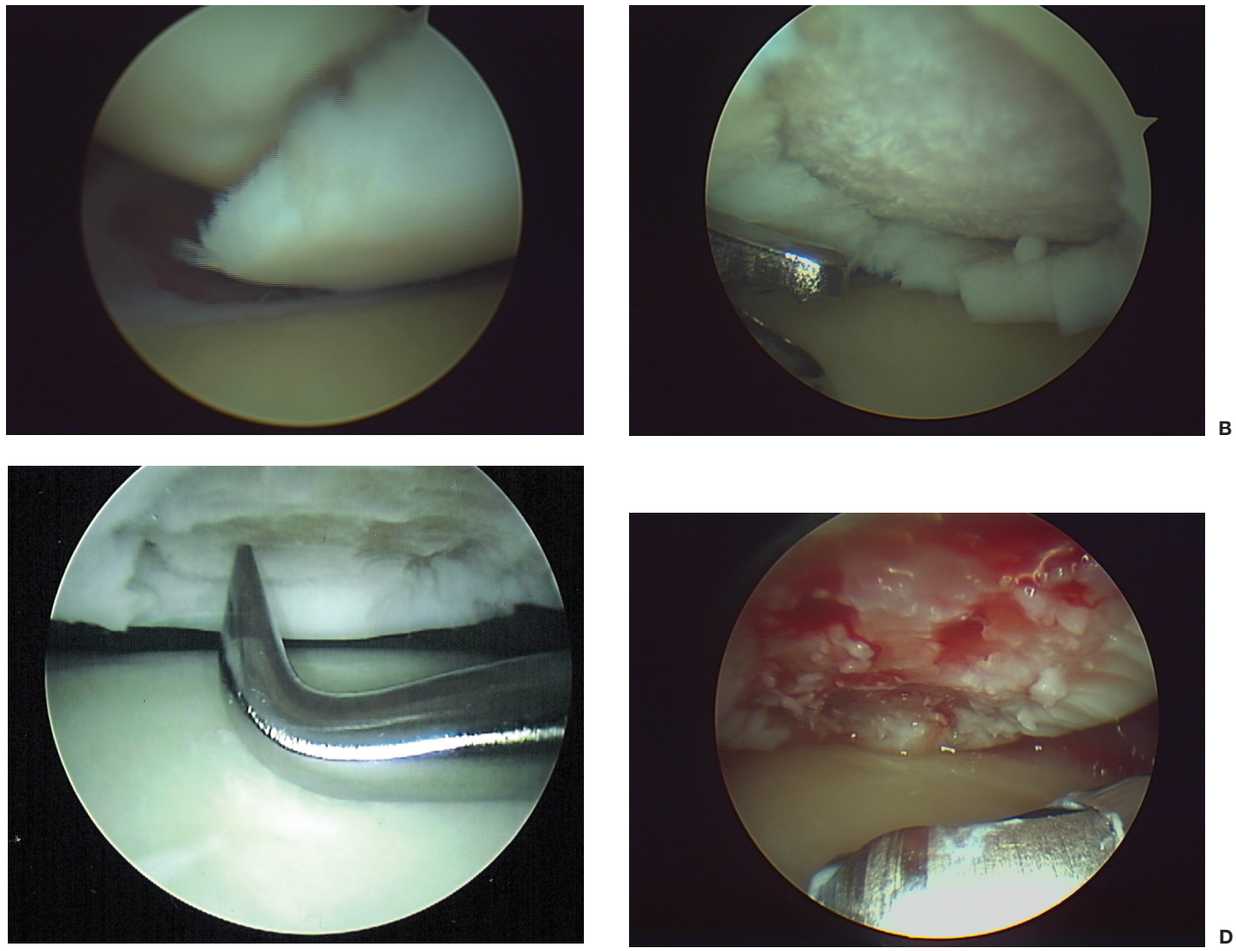

Fig 15-3. Shoulder arthroscopic visualization of cartilaginous defect treated with subchondral perforation technique (Steadman). Views are of a right shoulder, visualized from the posterior portal. **A:** Cartilaginous loose body visualized arthroscopically. **B:** Remaining defect following preliminary debridement. **C:** Arthroscopic awl employed for subchondral perforations. **D:** Final area of subchondral perforation showing good blood supply following the perforations.

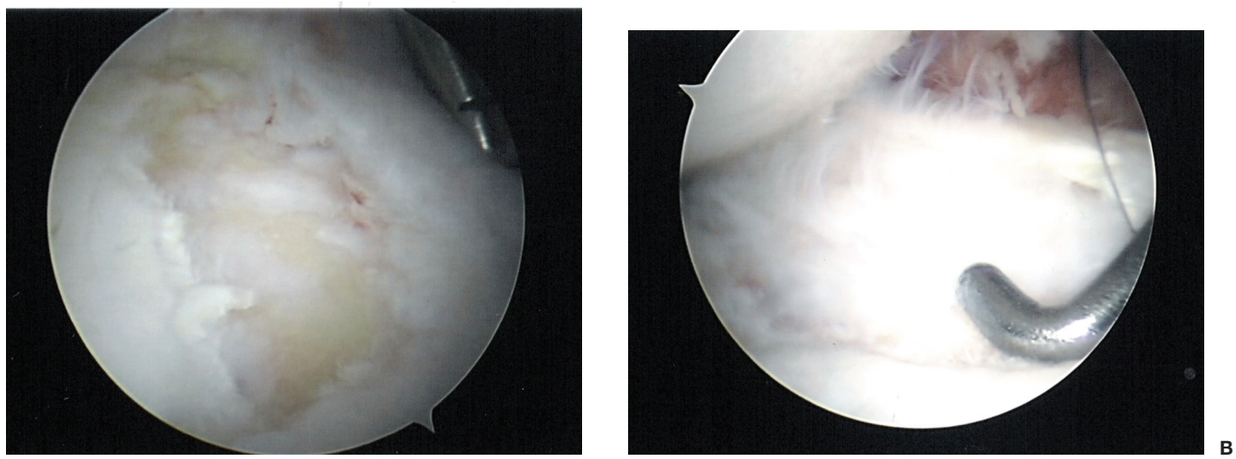

Fig 15-4. Follow-up lesions of subchondral perforation technique on the glenoid surface. **A:** Glenoid lesion at three-year follow-up showing some small, patchy areas of fibrocartilage. (Left shoulder, posterior portal view of mid-glenoid). **B:** Glenoid lesion at two-year follow-up showing more exuberant fibrocartilage repair. (Right shoulder, posterior portal view of mid-glenoid.)

they would have the surgery again. Most patients noted the onset of pain relief within 5 weeks of surgery, and obtained a duration of pain relief of 28 months or greater. The addition of concomitant procedures, such as acromioplasty, distal clavicle resection, and labral debridement or repair did not have a negative impact on the functional results. They did note, however, that lesions greater than 2 cm appeared to be associated with a return of pain and failure of the procedure.

SUMMARY

Full thickness chondral defects and osteochondral defects of the shoulder can cause numerous problems for the patient such as pain, swelling, locking, and may lead to early osteoarthritis. The goals of treatment are to alleviate pain and improve function as well as delay the need for prosthetic replacement of the joint.

A variety of alternatives is available to treat these lesions; however, many limitations exist. There are several techniques that include simple debridement that clearly help in the short term, but do not change the natural course of the disease process. In most situations, the best that can be achieved with debridements and abrasions is a fibrocartilaginous covering of the articular surface with poor biomechanical characteristics (48).

The results of resurfacing the cartilage lesions, whether performed with biological tissues or synthetic materials, appear to be promising; however, there is very little large scale or long term data to support the routine use of any one technique over another.

The symptomatology associated with the early arthritic shoulder can certainly be improved with the judicious use of the arthroscope; however, appropriate patient selection is critical in this regard as significant radiographic deformities certainly do not improve with this treatment modality.

REFERENCES

1. Bobic V. Arthroscopic osteochondral autogenous graft transplantation in anterior cruciate reconstruction: a preliminary report. *Knee Surg Sports Traumatol Arthrosc*. 1996;3:262–262.
2. Brittberg M, Nillsson A, Petersen H, et al. Treatment of deep cartilage defects in the knee with autologous chondrocyte transplantation. *N Engl J Med*. 1994;331:889–895.
3. Hangody L, Kish G, Karpati Z. Autogenous osteochondral graft technique for replacing knee cartilage defects in dogs. *Orthopedics*. 1997;5:175–181.
4. Bert JM. Abrasion arthroplasty. *Oper Tech Orthop*. 1997;4:294–299.
5. Mitchell N, Shepard N. Resurfacing of adult rabbit articular cartilage by multiple perforation of the subchondral bone. *J Bone Joint Surg*. 1976;58A:230–233.
6. Steadman JR, Rodkey WG, Singleton SB, et al. Microfracture technique for full thickness chondral defects. *Oper Tech Orthop*. 1997;7:300–307.
7. Carroll KW, Helms CA, Speer KP. Focal articular cartilage lesions of the superior humeral head: MR imaging findings in seven patients. *Am J Roentgenol*. 2001;176:393–397.
8. Guntern DV, Pfirrmann CW, Schmid MR. Articular cartilage lesions of the glenohumeral joint: Diagnostic effectiveness of MR arthrography and prevalence in patients with subacromial impingement syndrome. *Radiology*. 2002;226:165–170.
9. Ellman H, Harris E, Kay SP. Early degenerative joint disease simulating impingement syndrome: arthroscopic findings. *Arthroscopy*. 1992;8:482–487.
10. Feeney M, O'Dowd J, Kay EW, et al. Glenohumeral articular cartilage changes in rotator cuff disease. *J Shoulder Elbow Surg*. 2003; 12:20–23.
11. Bishop JY, Flatow EL. Management of glenohumeral arthritis: a role for arthroscopy? *Orthop Clin North Am*. 2003;34:559–566.
12. Cameron BD, Galatz LM, Ramsey ML, et al. Non-prosthetic management of grade IV osteochondral lesions of the glenohumeral joint. *J Shoulder Elbow Surg*. 2002;11:25–32.
13. Weinstein DM, Bucchieri JS, Pollock RG, et al. Arthroscopic debridement of the shoulder for osteoarthritis. *Arthroscopy*. 2000; 16:471–476.
14. Kelkar R, Wang VM, Flatow EL. Glenohumeral mechanics: a study of articular geometry, contact, and kinematics. *J Shoulder Elbow Surg*. 2001;10:73–84.
15. Buckwalter JD, Rosenberg L, Coutts R, et al. Articular cartilage: injury and repair. In: Woo L-Y, Buckwalter JA, eds. *Injury and Repair of the Musculoskeletal Soft Tissues*. Park Ridge, Ill: American Academy of Orthopaedic Surgeons; 1988:465–537.
16. Donohue JM, Buss DD, Oegema TR, et al. The effects of indirect blunt trauma on adult canine articular cartilage. *J Bone Joint Surg*. 1983;65A:948–957.
17. Imhof H, Breitenseher M, Kainberger F, et al. Importance of subchondral bone to articular cartilage in health and disease. *Top Magn Reson Imaging*. 1999;10:180–192.
18. Nakagawa Y, Ueo T, Nakamura T. A novel surgical procedure for osteonecrosis of the humeral head: reposition of the joint surface and bone engraftment. *Arthroscopy*. 1999;15:433–438.
19. Chen FS, Frenkel SR, Di Cesare PE. Repair of articular cartilage defects: part II. treatment options. *Am J Orthop*. 1999;28:88–96.
20. Hunziker EB. Articular cartilage repair: basic science and clinical progress. A review of the current status and prospects. *Osteoarthritis Cartilage*. 2003;10:4232–463.
21. Gerber A, Lehtinen JT, Warner JJP. Glenohumeral osteoarthritis in active patients. *Phys Sports Med*. 2003;31:401–410.
22. Miyauchi S, Machida A, Onaya J, et al. Alterations of proteoglycan synthesis in rabbit articular cartilage induced by intra-articular injection of papain. *Osteoarthritis Cartilage*. 1993;1: 253–262.
23. Regatte RR, Akella SVS, Bothakur A, et al. Proteoglycan depletion-induced changes in transverse relaxation maps of cartilage. *Acad Radiol*. 2002;9:1388–1394.
24. Denti M, Monteleone M, Trevisan C, et al. Magnetic resonance imaging versus arthroscopy for the investigation of the osteochondral humeral defect in anterior shoulder instability. A double blind prospective study. *Knee Surg Sports Traumatol Arthrosc*. 1995;3(3):184–186.
25. Chow JCY, Hantes ME, Houle JB, et al. Arthroscopic autogenous osteochondral transplantation for treating knee cartilage defects: a 2- to 5-year follow-up study. *Arthroscopy*. 2004;20:681–690.
26. Gerber C, Lambert SM. Allograft reconstruction of segmental defects of the humeral head for the treatment of chronic locked posterior dislocation of the shoulder. *J Bone Joint Surg*. 1996;78A: 376–382.
27. Hart R, Janecek M, Visna P, et al. Mosaicplasty for the treatment of femoral head defect after incorrect resorbable screw insertion. *Arthroscopy*. 2003;19:E80.
28. Scheibel M, Bartl C, Magosch P, et al. Osteochondral autologous transplantation for the treatment of full-thickness articular cartilage defects of the shoulder. *J Bone Joint Surg*. 2004;86B: 991–997.

29. Siebold R, Lichtenberg S, Habermeyer P. Combination of microfracture and periosteal-flap for the treatment of focal full thickness articular cartilage lesions of the shoulder: a prospective study. *Knee Surg Sports Traumatol Arthrosc*. 2003;11:183–189.
30. Carranza-Bencano A, Garcia-Paino L, Armas Padron JR, et al. Neochondrogenesis in repair of full-thickness articular cartilage defects using free autogenous periosteal grafts in the rabbit. A follow-up in six months. *Osteoarthritis Cartilage*. 2000;8:351–358.
31. O'Driscoll S, Fitzsimmons JS. The role of periosteum in cartilage repair. *Clin Orthop*. 2001;391(suppl):190–207.
32. Hominga GN, Bulstra SK, Bouwmeester PS, et al. Perichondral grafting for cartilage lesions of the knee. *J Bone Joint Surg*. 1990; 72B:1003–1007.
33. Minas T, Petersen L. Advanced techniques in autologous chondrocyte transplantation. *Clin Sports Med*. 1999;18:13–44.
34. Romeo AA, Cole BJ, Mazzocca AD, et al. Autologous chondrocyte repair of an articular defect in the humeral head. Case Report. *Arthroscopy*. 2002;18:925–929.
35. Flynn JM, Springfield DS, Mankin HJ. Osteoarticular allografts to treat distal femoral osteonecrosis. *Clin Orthop*. 1994;303:38–43.
36. Muscolo DL, Ayerza MA, Aponte Tinao LA. Distal femur osteoarticular allograft reconstruction after Grade III open fractures in pediatric patients. *J Orthop Trauma*. 2004;18:312–315.
37. Oka M, Noguchi T, Kumar P, et al. Development of an artificial articular cartilage: polyvinyl alcohol hydrogel (PVA-H). *Clin Mater*. 1990;6:361–381.
38. Oka M, Chang YS, Nakamura T, et al. Synthetic osteochondral replacement of the femoral articular surface. *J Bone Joint Surg*. 1997;79B:1003–1007.
39. Cofield RH, Frankle MA, Zuckerman JD. Humeral head replacement for glenohumeral arthritis. *Semin Arthroplasty*. 1995; 6:214–221.
40. Matthews LS, Labudde JK. Arthroscopic treatment of synovial disease. *Orthop Clin North Am*. 1993;24:101–109.
41. Iannotti JP, Naranja RJ, Warner JJP. Surgical management of shoulder arthritis in the young and active patient. In: Warner JJP, Iannotti JP, Gerber C, eds. *Complex and Revision Problems in Shoulder Surgery*. Philadelphia: Lippincott-Raven; 1997:289–302.
42. Klepps SJ, Galatz LM, Yamaguchi K. Arthroscopic treatment of osteoarthritis: Debridement and microfracture arthroplasty. In: Imhoff AB, Ticker JB, Fu FH, eds. *An Atlas of Shoulder Arthroscopy*. London: Martin Dunitz; 2003:359–365.
(Mankin HJ. The response of articular cartilage to mechanical injury. *J Bone Joint Surg*. 1982;64A:460–466.)
43. Blevins F, Steadman JR, Rodrigo JJ, et al. Treatment of articular cartilage defects in athletes: an analysis of functional outcome and lesion appearance. *Orthopedics*. 1998;21:761–768.
44. Walch G, Boulahia A, Boileau P. Primary glenohumeral osteoarthritis: clinical and radiographic classification. *Acta Orthop Belg*. 1998;64:46–52.
45. Cofield RH. Arthroscopy of the shoulder. *Mayo Clin Proced*. 1983;58:501–508.
46. Johnson CC. The shoulder joint: an arthroscopic perspective of anatomy and pathology. *Clin Orthop*. 1987;223:113–125.
47. Ogilvie-Harris DJ, Wiley AM. Arthroscopic surgery of the shoulder. *J Bone Joint Surg*. 1986;60B:201–207.
48. Newman AP. Articular cartilage repair. Current concepts. *Am J Sports Med*. 1998;26:309–324.