

# Acetabular Labral Tears With Underlying Chondromalacia: A Possible Association With High-Level Running

Carlos A. Guanche, M.D., and Robby S. Sikka, B.A.

---

**Purpose:** The use of hip arthroscopy has helped delineate intra-articular pathology and has enabled clinicians to further elucidate the factors responsible for injuries, such as running. The subtle development of degenerative changes may be a result of repetitive impact loading associated with this sport. This study presents a population of runners with common pathologic acetabular changes. **Type of Study:** Case series. **Methods:** Eight high-level runners with an average age of 36 years (range, 19 to 45 years) were seen for complaints of increasing hip pain with running without any history of macrotrauma. All of the patients had either run several marathons (4), were triathletes (1), Olympic middle distance runners (1), or had run more than 10 miles per week for longer than 5 years (2). Plain radiographic analysis revealed no degenerative changes and an average center-edge (CE) angle of 36.7° (range, 28° to 44°). **Results:** All patients underwent hip arthroscopy with labral debridement. In 6 patients (75%), a chondral injury of the acetabular cartilage underlying the labral tear was noted. In addition, 3 patients had ligamentum teres disruptions. **Conclusions:** It is possible that the development of these tears is the result of subtle instability, which may be exacerbated by running, eventually leading to labral tearing and possible ligamentum teres disruption. While perhaps concurrently, subtle acetabular dysplasia may play a role. Although this study does not confirm an association between running and the development of labral tears or chondral lesions in the hip, it certainly questions whether there is an injury pattern common to this population, a “runner’s hip.” **Level of Evidence:** Level IV. **Key Words:** Hip—Arthroscopy—Hip injuries—Running—Acetabular labrum—Ligamentum teres.

---

Recently, an explosion in the knowledge of hip pathology has occurred. The impetus has been the increasing use of magnetic resonance imaging (MRI) and MRI arthrography as well as arthroscopy to evaluate hip injuries. Increasingly, diagnostic and surgical procedures are being performed to evaluate intra-articular problems previously dealt with infrequently, if at all.

Tears of the acetabular labrum are often dealt with arthroscopically. Patterson<sup>1</sup> first described a torn acetabular labrum associated with posterior dislocations

of the hip in 1957. In these cases the displaced labrum was shown to be a block to concentric reduction of the hip. More subtle disruptions of the acetabular labrum were not reported until 1977, when 2 cases of hip pain without dislocation or major trauma were documented.<sup>2</sup> These patients were treated by arthrotomy and partial resection of the labrum. This study was the first to show that acetabular labral tears could present as the primary cause of hip pain and it led to further analysis of the acetabular labrum. Between 1986 and 1996, there were several reports on the relationship between dysplasia and acetabular labral tears.<sup>3,4</sup> Dorrrell and Catterall<sup>5</sup> described 1 case of acetabular labral tears associated with developmental dysplasia. Also Ikeda et al.<sup>6</sup> reported on 7 patients with arthroscopically documented labral tears associated with dysplastic conditions of the hip.

More recently, femoroacetabular impingement has been postulated as a cause of labral damage with

---

*From the Southern California Orthopedic Institute, Van Nuys, California, U.S.A.*

*Address correspondence and reprint requests to Carlos A. Guanche, M.D., Southern California Orthopedic Institute, 6815 Noble Ave, Van Nuys, CA 91405, U.S.A. E-mail: guanche@scoi.com*

*© 2005 by the Arthroscopy Association of North America  
0749-8063/05/2105-4102\$30.00/0*

*doi:10.1016/j.arthro.2005.02.016*

repetitive flexion and internal rotation of the hips.<sup>7</sup> In addition, the converse has been postulated by McCarthy and Lee.<sup>8</sup> Based on the reproduction of groin pain with hip extension, rather than flexion/rotation, the mechanism of labral degeneration is that of hyperextension and torsional forces acting on the labrum and subjacent articular cartilage.<sup>8</sup>

One group of patients that are prone to hip difficulties is runners. The subtle development of degenerative changes may be a result of repetitive impact loading associated with running and the rate of degeneration may be exacerbated by the presence of subtle acetabular deformities (possibly congenital). In addition, subtle instability with consequent hyperextension in the stride phase may be a source of recurrent subluxation and possibly attritional tearing of the labrum.<sup>9</sup> However, the exact association between repetitive impact and degeneration of the hip joint as a whole, or the labrum in particular, has yet to be established.<sup>10,11</sup> Intuitively, there may be an association between subtle dysplasia and the development of hip joint degeneration in competitive runners. Yet, in a study evaluating the association between running and the development of degenerative arthritis, there did not appear to be an increased incidence of degeneration in elite runners.<sup>10</sup> However, other studies have suggested that long-term, high-intensity, high-mileage running should not be dismissed as a potential risk factor for premature osteoarthritis of the hip.<sup>11</sup> Thus, there is no consensus on the effect of running on the development of osteoarthritis in the hip. Moreover, those with previous traumatic incidents, or malalignment, are still at risk of increased intra-articular problems.

Following the report of Suzuki et al.<sup>12</sup> on the arthroscopic diagnosis of acetabular labral tears in 1986, hip arthroscopy has grown. Acetabular labral injuries are now widely recognized in a variety of athletes. A majority of these tears occur in the anterior or antero-superior acetabular labrum, with the most common type being a radial flap tear.<sup>13-15</sup> Most of these injuries have been documented in football, soccer, and ballet. In essence, any sport involving repetitive twisting maneuvers appears to place the athlete at risk of this injury.<sup>16,17</sup>

Yet to date, there have been few reported cases of runners with acetabular labral tears. It is likely that as hip arthroscopy expands, an increasing number of runners will be found to have acetabular labral tears.<sup>13</sup> In this article, we present a series of acetabular labral tears in high-level runners found to have a common constellation of intra-articular pathology.

## METHODS

Between March 2000 and May 2003, 162 hip arthroscopies were performed by the senior author (C.A.G.). A retrospective review of these patients was performed to identify high-level runners within the group. The definition of a high-level runner was either an Olympic or college runner or a person having participated in more than 5 marathons. Eight high-level runners with an average age of 36 years (range, 19 to 45 years) were identified. Six patients were female and 2 were male, with the right hip joint affected in 5. None of the subjects had any underlying pathologic condition or history of macrotrauma to the extremity. Medical records, imaging studies, and arthroscopic findings were reviewed. All patients were given the Western Ontario and McMaster Universities Osteoarthritis Index (WOMAC) survey at their follow-up examination.<sup>18</sup> The duration of clinical and radiographic follow-up ranged from 6 to 29 months (average, 14 months).

## RESULTS

### Symptoms and Physical Findings

All patients complained of an increasing amount of discomfort over the anterior groin area, with an increasing inability to run at their previous levels. All cases were unilateral with respect to the complaints of pain and catching. All of the patients had either run several marathons (4), were triathletes (1), were Olympic middle distance runners (1), or had run more than 10 miles per week for longer than 5 years (2).

The symptomatology was insidious, with none of the patients reporting even remote trauma to the involved extremity. In all cases, the patients had undergone an extended rehabilitation course, including core strengthening and joint mobilization. Two patients received intra-articular cortisone injections and had mild relief for short periods.

All of the patients complained of pain beginning at the start of their runs, progressing in severity with increasing mileage. In 2 of the patients, there had been an inability to run altogether as a result of pain. Four of the patients complained of mechanical catching within the joint. No patient experienced radicular symptoms.

Physical examination of the patients revealed a normal and symmetrical range of motion in their hips. One patient had a limb-length discrepancy of approximately 2 cm, with the affected side being longer.

There was no evident muscle asymmetry in any of the involved limbs compared with the contralateral lower extremity. In all cases, there was significant pain exacerbation and reproduction of the symptomatology with forced flexion with internal rotation of the hip.<sup>19</sup>

### Radiographic Image Analysis

All of the patients underwent plain radiographic analysis. The center-edge (CE) angle measurement averaged 36.7° (range, 28° to 44°) (Table 1). No radiographs showed degenerative changes. There was no evidence of pre-existing slipped capital femoral epiphyses in any patient.

All patients underwent preoperative MRI. In 2 patients whose scans did not include the use of intra-articular contrast, there was no evident labral pathology. The scans were performed at outlying institutions and are an indication of the authors' tertiary referral base. The tears were located predominantly in the anterosuperior portion of the labrum. MRI interpretation revealed no other significant findings in any of the patients. Specifically, no cartilage or ligamentum abnormalities were noted either prospectively or retrospectively.

### Arthroscopic Findings and Treatment

All of the patients underwent hip arthroscopy in the supine position, using fluoroscopic guidance for portal establishment.<sup>19</sup> All patients were documented to have labral tears in the 10- to 12-o'clock anterosuperior region (fight hip). In 6 patients (75%), there was also a chondral injury to the acetabular cartilage adjacent to the labral tear. Using the Outerbridge classification, these lesions were all grade III in nature and were directly under the area of labral tearing for the extent of the labral lesion (Fig 1).<sup>20</sup> In addition, 3 cases revealed ligamentum teres disruptions (Fig 2). Two of

these were in patients with MRI arthrograms and 1 was in an unenhanced study. Surgical treatment included debridement of the labral tears, chondral debridement, and debridement of the disrupted ligamentum.

### WOMAC and Follow-up

All patients completed the WOMAC scoring scale postoperatively at an average of 14 months (range, 6 to 29 months). The average value was 94 (Table 1). All patients were able to return to running at their preinjury level, with the patient with the 6-month follow-up having begun to run 10-km races at last follow-up.

## DISCUSSION

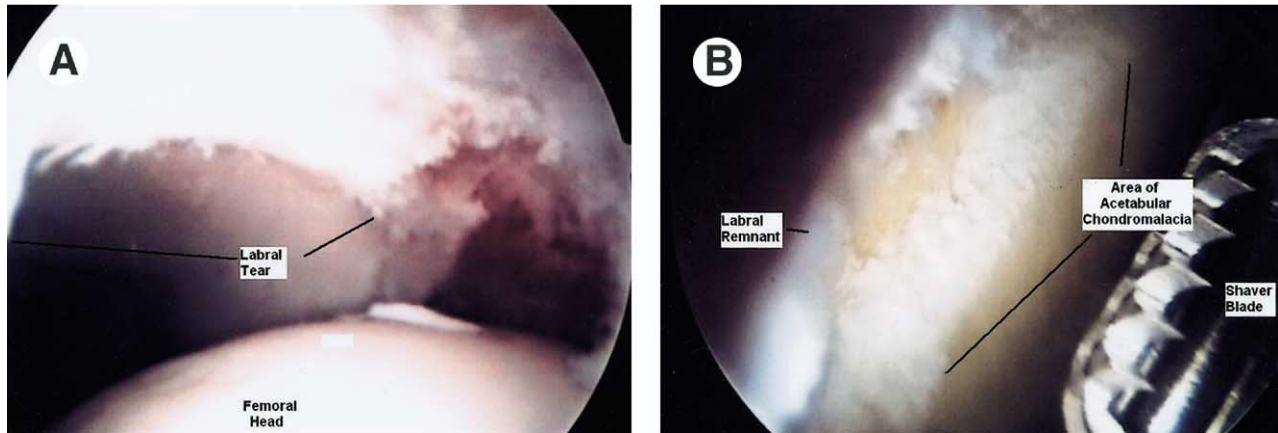
The acetabular labrum is a fibrocartilaginous rim that surrounds the perimeter of the acetabulum, with the transverse acetabular ligament completing the rim at the base. The labrum is generally triangular in cross-section and deepens the acetabulum ostensibly to increase the constraint of the hip joint. Theoretically, the congruency of the hip makes the labrum less important in maintaining joint stability compared with the glenoid labrum in the shoulder.<sup>21-24</sup>

In western cultures, the most common location for tears of the labrum is the anterior articular margin.<sup>5,13,14,25</sup> There are several possible reasons for this, including inferior intrinsic mechanical properties, greater physical stress, and the fact that hypovascularity may lead to degeneration.<sup>25</sup>

Studies examining the exact contribution of the labrum in maintaining the congruency of the femoral head in extreme positions have not yet been reported. The unloaded acetabulum has a smaller diameter than the femoral head and, in extreme positions of flexion,

TABLE 1. Patient Demographics

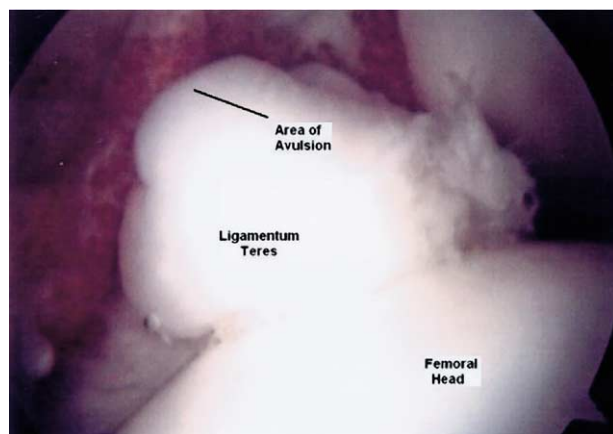
Patient	Age (yr)	Average Miles Run per Week	Time Running at High Level	CE (°)	WOMAC: Nonaffected Hip/Affected Hip	Labral Tear	Ligamentum Tear	Chondromalacia
Male	34	40/wk	7 yr	40	100/100	10-2	Yes	Grade III
Female	40	20/wk	10 yr	28	100/98	10-2	No	Grade III
Male	40	35/wk	6 yr	35	100/92	10-2	No	Grade III
Female	34	12/wk	5 yr	44	85/80	10-2	No	NA
Female	33	60/wk	10 yr	40	100/100	10-2	No	Grade III
Female	45	20/wk	10 yr	35	100/100	10-2	Yes	NA
Female	43	20/wk	5 yr	42	96/92	10-2	No	Grade III
Female	19	15/wk	4 yr	30	96/90	10-2	Yes	Grade III
Average	36	27.75/wk	7 yr	36.7	97/94			



**FIGURE 1.** A typical degenerative labral tear with an underlying chondral lesion in a right hip as viewed from the anterolateral portal. (A) View of labral degenerative area from 10 to 12 o'clock. (B) After debridement of the labrum and underlying chondral lesion. Note the area indicated by the lines showing the anterior and posterior extent of the lesion.

it is likely that there could be greater incongruity between the femoral head and acetabulum.<sup>26-28</sup> This could lead to the labrum being a load-bearing structure within the hip.<sup>21</sup> However, Konrath et al.<sup>29</sup> reported that the labrum did not significantly contribute to stress distribution or load transfer within the acetabulum.<sup>25,29</sup> Nonetheless, it is believed that the labrum may contribute to the negative intra-articular pressure in the joint, thereby enhancing stability. The contribution of the labrum to joint stability is expected to be greatest at extremes of motion, where impingement may cause traumatic dislocation.<sup>30</sup> Thus, the exact function and role of the acetabular labrum is still undetermined.

The hip joint is exposed to an inordinate amount of



**FIGURE 2.** Tear of the ligamentum teres with significant inflammatory tissue around the chronically avulsed hypertrophic tissue.

force during athletic activities. Few studies have examined the exact role of the labrum in extreme positions, but it is clear that episodic or repetitive maneuvers at the extremes of motion are responsible for some labral pathologies.<sup>13,21,30</sup> Sports that involve external rotation of the hips, such as golf, soccer, or hockey, can account for many of these hip injuries.<sup>13,21,25</sup> However, running and jumping can generate forces across the hip joint of 3 to 5 times body weight. It has been estimated that 11% of all hip injuries are in runners, and an increasing number of these injuries are tears of the acetabular labrum.<sup>17</sup>

Typically, hyperextension along with femoral external rotation is the most common cause of acetabular labral tearing. Most of these tears occur in the anterior region of the labrum where more than two thirds of all tears are reported.<sup>5,13,14,25</sup> Superior labral tears are likely caused by repetitive loading motions, often seen in runners. Posterior tears are often caused by axial loading of the hip in a flexed position.<sup>13,21</sup> In addition, femoroacetabular impingement has been postulated to be responsible for anterior labral lesions.<sup>7</sup> Theoretically, the flexibility required for many sports, particularly dancing and gymnastics, creates a selection system for those with greater physiologic arcs of hip motion.<sup>30</sup> In our study, all 8 subjects had tears in the 10- to 12-o'clock region, indicating an area of the labrum that may be predisposed to increased load bearing during running even without the presence of malalignment.

There is a high association between labral lesions and degeneration of the cartilage surface. McCarthy et al.<sup>25</sup> reported that 74% of their patients with labral

tears had chondral damage. Moreover, in 80% of these patients, the chondral damage was in the same zone as the labral lesion.<sup>25</sup> The strongest association between articular damage and labral lesions was present laterally and posteriorly. Additionally, the severity of cartilage damage was greater in patients with labral fraying. In our study, 75% of the patients had chondral injuries and all of these were grade III Outerbridge lesions. Articular cartilage degeneration originates in the anterosuperior portion of the weight-bearing area of the femoral head and acetabulum, probably as a result of the high compressive stresses.<sup>25,15</sup> An excessive torsional and shear force that cannot be dissipated by the labrum causes a tear in the labrum, which then separates the attachment to the acetabular cartilage. This watershed zone separation, once initiated, can extend further. Continued loading may lead to delamination and degeneration.<sup>8</sup> Thus, it is important to evaluate patients with labral tears for chondral injuries.

Tears of the ligamentum teres are uncommon. Gray and Villar<sup>31</sup> reported on a series of 20 patients with ligamentum teres pathology out of 427 hip arthroscopies. Of the 20 patients with tears, 7 had complete avulsions. In our study, 3 of 8 patients had complete avulsions of the ligamentum teres (Fig 2). These all appeared to be chronic in nature and not caused by the intraoperative traction. Tears of the ligamentum teres are often associated with labral lesions and articular surface damage.<sup>31</sup> However, patients with complete avulsions of the ligamentum often have a history of major joint disruption from trauma or surgery or may have dysplasia of the hip.<sup>31</sup> In our study, none of the patients reported a specific macrotraumatic event, and none had dysplastic conditions. It is likely that the repetitive hyperextension from running led to subtle instability, thereby placing an inordinate amount of stress on the ligamentum with subsequent failure.

In the 3 cases of ligamentum teres avulsions, MRI did not indicate the ligamentum lesion (2 with intra-articular contrast). Therefore, in cases of labral tears it is important to visualize the ligamentum teres. Arthroscopic debridement of the stump should then be completed.

The authors theorize that the repetitive hyperextension seen in the stride phase of running leads to a subtle instability and increasing stress at the cartilage-labral junction. This may lead to the pathologic findings documented in this study, including labral tearing and associated chondral degeneration. Based on this mechanism, femoroacetabular impingement does not

appear to be a factor, although offset was not specifically analyzed.

While the emphasis of this study is to bring to light the possible association of high-level running with labral and acetabular degeneration, the shortcomings are obvious. First, this is a retrospective review based on 1 surgeon's experience with a relatively new procedure. The learning curve for hip arthroscopy is known to be high. Whether the incidence of these injuries is less as a result of failure to make the diagnosis prospectively is a notable criticism.

The use of the WOMAC score can also be criticized. There truly is no validated scoring scale available to analyze an active population with hip injuries.<sup>32</sup> The WOMAC score measures pain, stiffness, and physical function in patients with arthritis. It is self-administered, simple, reliable, and validated. This was the reason the WOMAC was used in this study. Although efforts are underway to validate other scoring scales, none other has yet surfaced for this purpose.<sup>32</sup>

However, the major limitation is the failure to prove the direct association of running and the described pathologic entities. While runners typically run for the majority of their training, they certainly participate in other activities that could contribute or perhaps be solely responsible for the documented labral and cartilage abnormalities. The only sure way of determining the veracity of the findings in this study is to perform prospective analyses on this population. The senior author has begun such a study, but this will clearly take many years before useful conclusions can be drawn.

Although the hip and pelvis account for 5% to 6% of injuries in adult athletes and 10% to 24% of injuries in child athletes, the hip has received less attention than other major joints.<sup>17</sup> Until recently, we have been less sophisticated in our ability to diagnose hip injuries with considerably less technology available to treat and diagnose these injuries.<sup>16</sup> Through improved clinical, imaging, and arthroscopic techniques, more accurate associations of pathologic entities with specific mechanisms may be possible.

## CONCLUSIONS

Although most reports of acetabular labral injuries have focused on soccer, football, hockey, and other sports involving twisting motions, high-level runners may be predisposed to tears of the anterosuperior portion of the labrum. In cases where runners have maintained a high intensity and high mileage for a lengthy period, it is important to consider tears of the

labrum as a potential diagnosis. On arthroscopic examination, it is also important to visualize the chondral surface in the area of the labral tear, given the high incidence of chondral defects in our patients. It is also important to visualize the ligamentum teres and deal with any pathology in that area.

Although this study does not confirm an association between running and the development of labral tears or chondral lesions in the hip, it certainly questions whether there is an injury pattern that is common to this population, a "runners hip." Further prospective, longitudinal studies should be planned to delineate this further.

## REFERENCES

- Patterson JM. The torn acetabular labrum: A block to reduction of a dislocated hip. *J Bone Joint Surg Br* 1957;39:306-309.
- Altenberg AR. Acetabular labral tears: A cause of hip pain and degenerative arthritis. *South Med J* 1977;70:174-175.
- Nishina T, Saito S, Ohzono K, et al. Chiari pelvic osteotomy for osteoarthritis: The influence of torn and detached acetabular labrum. *J Bone Joint Surg Br* 1990;72:765-769.
- Klaue K, Durnin C, Ganz R. The acetabular rim syndrome. *J Bone Joint Surg Br* 1991;73:423-429.
- Dorrell J, Catteral A. The torn acetabular labrum. *J Bone Joint Surg Br* 1986;68:400-403.
- Ikeda T, Awaya G, Suzuki S, et al. Torn acetabular labrum in young patients. *J Bone Joint Surg Br* 1988;70:13-16.
- Ito K, Minka MA, Leunig M, et al. Femoroacetabular impingement and the cam-effect. A MRI-based quantitative anatomical study of the femoral head-neck offset. *J Bone Joint Surg Br* 2001;83:171-176.
- McCarthy J, Lee J. Acetabular dysplasia: A paradigm of arthroscopic examination of chondral injuries. *Clin Orthop Rel Res* 2002;405:122-128.
- Philippon MJ. The role of arthroscopic thermal capsulorrhaphy in the hip. *Clin Sports Med* 2001;20:817-829.
- Sohn RS, Lyle M. The effect of running on pathogenic osteoarthritis of the hips and knees. *Clin Orthop* 1985;198:106-109.
- Marti B, Knoblach MB, Tschopp A, et al. Is excessive running predictive of degenerative hip disease? Controlled study of former elite athletes. *BMJ* 1989;299:91-93.
- Suzuki S, Awaya G, Suzuki S, et al. Arthroscopic diagnosis of ruptured acetabular labrum. *Acta Orthop Scand* 1986;57:513-515.
- Fitzgerald R. Acetabular labral tears. *Clin Orthop* 1995;311:60-68.
- Farjo LA, Glick JM, Sampson TG. Hip arthroscopy for acetabular labrum tears. *Arthroscopy* 1999;15:132-137.
- Noguchi Y, Miura H, Takasugi S, et al. Cartilage and labrum degeneration in the dysplastic hip generally originates in the anterosuperior weight-bearing area: An arthroscopic observation. *Arthroscopy* 1999;15:496-506.
- Byrd JWT, Jones KS. Hip arthroscopy in athletes. *Clin Sports Med* 2001;20:749-761.
- Scopp JM, Moorman CT. The assessment of athletic hip injury. *Clin Sports Med* 2001;20:647-659.
- Bellamy N, Buchanan WW, Goldsmith CH, et al. Validation study of WOMAC: A health status instrument for measuring clinically important patient relevant outcomes to antirheumatic drug therapy in patients with osteoarthritis of the hip or knee. *J Rheumatol* 1988;15:1833-1840.
- Byrd JWT. Investigation of the symptomatic hip: Physical examination. In: Byrd JWT, ed. *Operative hip arthroscopy*. New York: Thieme, 1998;25-42.
- Outerbridge R. The etiology of chondromalacia patellae. *J Bone Joint Surg Br* 1961;43:752-754.
- Mason JB. Acetabular labral tears in the athlete. *Clin Sports Med* 2001;20:779-790.
- Dvorak M, Duncan CP, Day B. Arthroscopic anatomy of the hip. *Arthroscopy* 1990;6:264-273.
- Keene GS, Villar RN. Arthroscopic anatomy of the hip: An in vivo study. *Arthroscopy* 1994;10:392-399.
- Kim YT, Azuma H. The nerve endings of the acetabular labrum. *Clin Orthop* 1995;320:176-181.
- McCarthy J, Noble P, Aluisio FV, et al. Anatomy, pathologic features, and treatment of acetabular labral tears. *Clin Orthop* 2003;406:38-47.
- Afoke NY, Byers PD, Hutton WC. The incongruous hip joint: A casting study. *J Bone Joint Surg Br* 1980;62:511-514.
- Bullough P, Goodfellow J, Greenwald AS, et al. Incongruent surfaces in the human hip joint. *Nature* 1968;217:1290-1294.
- Greenwald AS, Haynes DW. Weight-bearing areas in the human hip joint. *J Bone Joint Surg Am* 1972;54:157-163.
- Konrath GA, Hamel AJ, Olson SA, et al. The role of the acetabular labrum and the transverse acetabular ligament in load transmission in the hip. *J Bone Joint Surg Am* 1998;80:1781-1788.
- Byrd JWT. Labral lesions: An elusive source of hip pain: Case reports and review of the literature. *Arthroscopy* 1996;12:603-612.
- Gray AJ, Villar RN. The ligamentum teres of the hip: An arthroscopic classification of its pathology. *Arthroscopy* 1997;13:575-578.
- Christensen CP, McCarthy JC, Mittleman MA, et al. Outcomes. In: McCarthy JC, ed. *Early hip disorders*. New York: Springer-Verlag, 2003;195-200.